

# Immunohistochemical Expression of Epidermal Growth Factor Receptor in Head and Neck Squamous Cell Carcinoma

Moniba Zafar<sup>1</sup>, Shoaib Naiyar Hashmi<sup>1</sup>, Malik Jawad Faisal<sup>2</sup>, Rabia Ahmed<sup>1</sup> and Syed Salman Ali<sup>1</sup>

## ABSTRACT

**Objective:** To determine the frequency of expression of epidermal growth factor receptor (EGFR) by immunohistochemistry in head and neck squamous cell carcinoma (HNSCC).

**Study Design:** Cross-sectional study.

**Place and Duration of Study:** Armed Forces Institute of Pathology (AFIP), Rawalpindi, from September 2015 to March 2016.

**Methodology:** Fifty-two cases of head and neck squamous cell carcinoma diagnosed on H&E stain were included in the study. Patients' gender and age were noted. Immunohistochemistry for EGFR was applied and the results were recorded. The data were analyzed by using computer software program SPSS version 19. Descriptive statistics, frequencies and percentages were calculated.

**Results:** Out of the 52 patients of HNSCC, 37 patients were males and 15 females. The age of the patients was between 21 and 80 years with an average age of  $58.58 \pm 12.63$ . Out of 52 cases, 45 cases (86.53%) were positive for EGFR while 7 cases (13.46%) were negative for EGFR. Significant statistical association was not seen between the tumour grade and EGFR expression ( $p=0.162$ ).

**Conclusion:** The high expression of EGFR in head and neck cancers among Pakistani patients suggests its value as a therapeutic target. EGFR inhibitors have become well-known part of HNSCC treatment; therefore, patients with EGFR positive HNSCC can be benefitted from the therapy.

**Key Words:** EGFR. Head and neck. Squamous cell carcinoma. Tumour grad.

## INTRODUCTION

The head and neck cancer (HNC) is one of the most prevalent cancers worldwide. It accounts for 3% of all cancers in the United States.<sup>1</sup> HNC comprises carcinomas of the upper aerodigestive tract, the sites of involvement being lip, oral cavity, nasopharynx and larynx.<sup>2</sup> The most common histologic type is head and neck squamous cell carcinoma (HNSCC). The primary risk factors associated with HNC include tobacco use and alcohol consumption. Other risk factors include human papilloma virus (HPV) infection for oropharyngeal cancer.<sup>3</sup>

The epidermal growth factor receptor (EGFR) is a transmembrane receptor protein which belongs to the ErbB receptor family. It is a 17-kDa glycoprotein, encoded by a gene located on chromosome 7p12.<sup>4</sup> The expression of EGFR appears to be an independent prognostic factor of overall survival.<sup>5</sup> The overexpression or mutation of EGFR in HNSCC is associated with poor prognosis and decreased survival.<sup>6</sup> The quantitative evaluation of EGFR can be carried out by immuno-

histochemistry (IHC) and has emerged as a convenient and promising marker for clinical outcome correlation.<sup>7</sup>

Literature shows variable results in the incidence of immunohistochemical expression of EGFR. In a study carried out in Sudan, EGFR was expressed in 84% of the HNC.<sup>7</sup> In a study conducted in Iraq EGFR was expressed in 87.5% of HNC,<sup>8</sup> while its expression was 90% of HNC in the study carried out in North Carolina.<sup>9</sup>

Determination of EGFR expression by immunohistochemistry in HNC in our population is necessary because there is variability in frequency of expression in various regions. As anti-EGFR therapy is currently available, the results of this study are likely to prove beneficial for the clinicians/oncologists to select the right patients for molecular targeted therapy against EGFR.

The objective of this study was to determine the frequency of expression of EGFR by immunohistochemistry in head and neck squamous cell carcinoma (HNSCC).

## METHODOLOGY

This cross-sectional study was carried out at the Armed Forces Institute of Pathology, Rawalpindi, from September 2015 to March 2016, after taking approval from the Ethical Review Committee. Fifty-two cases of head and neck squamous cell carcinoma were selected by consecutive, non-probability sampling. Patient data including age, gender, tumour grade and site of tumour were noted. Immunohistochemistry (IHC) analyses of human epidermal growth factor receptor (EGFR) were

<sup>1</sup> Department of Histopathology, Armed Forces Institute of Pathology, Rawalpindi.

<sup>2</sup> Department of ENT, Federal General Hospital, Islamabad.

Correspondence: Dr. Moniba Zafar, Trainee Histopathology, Armed Forces Institute of Pathology, Rawalpindi.

E-mail: monibazafar@gmail.com

Received: September 07, 2016; Accepted: April 25, 2017.

performed on formalin-fixed, paraffin embedded on head and neck squamous cell carcinoma tissue. Tissue blocks were sectioned at 3µm thickness and deparaffinized in xylene and rehydrated with decreasing concentration of ethanol. Heat induced epitope retrieval in Tris/EDTA buffer at pH 9.0 buffer was used for ready to use primary antibodies EGFR (clone by Biodiagnostic). EGFR staining was defined in a cytoplasmic or membranous pattern as 0- = negative (no staining), 1+ = weak staining (light brown color), 2+ = moderate staining (dark brown color), and 3+ = strong staining (very dark brown color). Score 0 or 1+ was taken as negative and 2+ or 3+ was taken as positive.<sup>9</sup>

The data was analyzed by using computer software program SPSS version 19. Frequencies and percentages were recorded for categorical variables while mean and standard deviations were calculated for the quantitative variables. A statistical analysis among age, gender, tumour grade and EGFR expression was done using chi-square test. P-value <0.05 was considered as significant.

### RESULTS

A total of 52 cases of head and neck squamous cell carcinoma were included from September 2015 to March 2016. The age of patients ranged from 21 to 80 years with a mean age of 58.58 ±12.63 years (Figure 1). Most of the patients belonged to 5th and 6th (46.2%, n=24) decade of life.

There were 37 (71.2%) males and 15 (28.8%) females with a male to female ratio of 2.5:1. The most common location of the tumour was the oral cavity (26.9%, n=14), followed by the glottis (21.2%, n=11), tongue (17%, n=09), alveolus and transglottis (7.7%, n=04) supraglottis, hypopharynx and tonsils (5.8%, n=03) and paranasal sinus (1.9%, n=01). Thirty-three patients (63.5%) were included in well differentiated grade, 16 (30.8%) in moderately differentiated grade and only 3 patients (5.8%) fallen into poorly differentiated grade.

Thirty-six cases of HNSCC (69.2%) showed strong intensity for EGFR, 9 cases (17.3%) moderate intensity, 5 cases (9.6%) mild intensity, while 2 cases (3.8%)

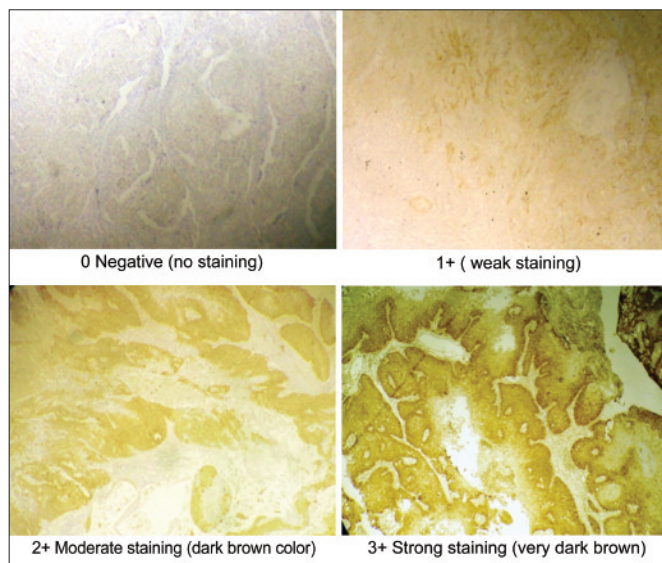


Figure 1: Expression of EGFR.

showed no staining. Therefore, 45 cases (86.53%) were considered positive for EGFR expression and 7 cases (13.46%) were negative for EGFR expression (Figure 1).

Non-significant statistical association was seen between tumour grade and EGFR expression with p-value of 0.162 (Table I).

### DISCUSSION

HNSCC is the most common malignancy in the head and neck region having geographical variation in the incidence and anatomic distribution of HNSCC worldwide.<sup>10</sup> Mitogenic signaling pathways of EGFR and its ligand, transforming growth factor-alpha (TGF-alpha), are upregulated in HNSCC.<sup>11</sup> EGFR expression increases progressively with increasing degree of dysplasia and is markedly elevated in fully transformed HNSCCs.<sup>12</sup> It is relatively less studied within the Asian populations, particularly Pakistani population. Moreover, there is no local study available for the frequency expression of EGFR.

In this study, males represented two-thirds of the affected patients (71.2%, n=37) with male to female ratio

Table I: Stratification of EGFR expression according to age groups, gender and tumour grade.

Clinicopathological variable	Cases (n)	Percentage (%)	EGFR Expression				p-value
			No	Mild	Moderate	Strong	
Age groups (years) (n=52)							
21-40	5	10%	1	-	-	4	0.02
41-60	24	46%	-	4	1	19	
61-80	23	44%	1	1	8	13	
Gender (n=52)							
Male	37	71%	-	3	8	26	0.08
Female	15	29%	2	2	1	10	
Tumour grade (n=52)							
Well differentiated	33	63.5%	1	-	-	24	0.162
Moderately differentiated	16	30.7%	-	2	4	10	
Poorly differentiated	3	5.7%	1	-	-	2	

of 2.5:1. This is in concordance with study conducted by Parkin *et al.* in France,<sup>13</sup> in which male to female ratio was 2:1 and Larizadeh *et al.* in Iran where the ratio was 1.47:1.<sup>14</sup>

The mean patient age in this study was 58.58 ±12.63 years. This is in agreement with Naz *et al.* in Pakistan where mean age was 56 years (n=68),<sup>15</sup> and Novin *et al.* in Iran where mean age was 58 years.<sup>16</sup> This mean age was 10 years younger when compared to Slootweg *et al.*; the mean age of their patients being 64 years.<sup>17</sup>

Mean age of the male patients in this study was 58 ±12.39 years (n=37) while that of female patients was 58.57 ±12.65 years (n=15). Comparison with a study carried out in São Paulo by de Carvalho *et al.* showed that the mean age of women suffering from OSCC was 60.7 years while that of males was 55.6 years.<sup>18</sup> Most of the present reported patients, (90%), belonged to 5th and 6th decade of life (n=47). In all, 9.61% of the patients were younger than 41 years of age.

In this study, the most common location of the tumors was the oral cavity. Oral cavity was also the commonest affected site in study by Naz *et al.* in Pakistan (n=68)<sup>15</sup> and Shay *et al.* in Los Angeles.<sup>19</sup> Larynx was the commonest tumour site in study by Novin *et al.* (55% of all patients),<sup>16</sup> and Larizadeh *et al.* in Iran (46.76% of the patients). In a study carried out by Cho *et al.*, hypopharynx was most affected site (98.7%),<sup>20</sup> while tongue was the most affected site (98.7%) in the study conducted by Andisheh-Tadbir *et al.* in Iran.<sup>21</sup>

Most of these cases of HNSCC were well differentiated (63.5%, n=33). This is in concordance with data from Andisheh-Tadbir *et al.* in Iran but is in contrast to data from a study carried out by Effiom *et al.* in Nigeria, where poorly differentiated SCC was the most common subtype (47.6%).<sup>22</sup>

In this study, the well differentiated tumours were highest in oral cavity (n=10) which is in concordance with the study of Roland *et al.* carried out in UK. Most common location of poorly differentiated tumours in this study was the oral cavity (n=2). However, most of poorly differentiated tumours were located in the pharynx in the study carried out by Roland *et al.*<sup>23</sup>

In this study, EGFR expression was observed in 86.53% (n=45). Our results are in concordance with studies carried out in Sudan, Iraq, and North Carolina where EGFR was expressed in 84%, 87.5% and 90% of the HNSCC respectively.<sup>7-9</sup> Maiti *et al.* in India analyzed in 30 dysplastic head and neck lesions and 148 HNSCC samples which showed expression of EGFR in 66-84% of the cases.<sup>24</sup> The studies conducted by Brunner *et al.* in Germany, showed a low expression of EGFR as compared to our population; expression being 49.4%, 38-43% and 25% respectively.<sup>25</sup>

## CONCLUSION

The expression of epidermal growth factor receptor in head and neck squamous cell carcinoma in this study population was 86.53%. The patients with HNSCC may be tested for EGFR by immunohistochemistry as it may be helpful for the oncologists to correlate it with response to anti-EGFR therapy combined with radiotherapy. However, the clinicopathological behaviour of HNSCC and expression of EGFR needs to be studied on a larger scale to see a true picture of this entity in the Pakistani population.

## REFERENCES

1. Seigel R, Ma J, Zou Z, Jemal A. Cancer statistics, 2014. *CA Cancer J Clin* 2011; **64**:9.
2. Nikakhlagh S, Saki N, Shoar MH, Sartipipor A, Saki S. Incidence of etiologic factors in squamous cell carcinoma of head and neck in Ahvaz. *Iran J Otorhinolaryngol* 2012; **24**:85-90.
3. Goon PK, Stanley MA, Ebmeyer J, Steinstrasser L, Upile T, Jerjes W, *et al.* HPV and head and neck cancer: A descriptive update. *Head Neck Oncol* 2009; **1**:36.
4. Shaib W, Kono S, Saba N. Antiepidermal growth factor receptor therapy in squamous cell carcinoma of the head and neck. *J Oncol* 2012; **2012**:521215.
5. Su NW, Leu YS, Lee JC, Liu CJ, Cheng CY, Lin JS, *et al.* EGF and EGFR genetic polymorphisms predict prognosis in locally advanced pharyngolaryngeal squamous cell carcinoma patients receiving postoperative concurrent chemoradiotherapy. *Onco Targets Ther* 2014; **7**:2197-204.
6. Hoffmann TK, Schirlau K, Sonkoly E, Brandau S, Lang S, Pivarcsi A, *et al.* A novel mechanism for anti-EGFR antibody action involves chemokine-mediated leukocyte infiltration. *Int J Cancer* 2009; **124**:2589-96.
7. Abusail MS, DirweeshAM, Salih RA, Gadelkarim AH. Expression of EGFR and p53 in head and neck tumors among Sudanese patients. *Asian Pac J Cancer Prev* 2013; **14**:6415-8.
8. Sarkis SA, Abdullah BH, Abdul Majeed BA, Talabani NG. Immunohistochemical expression of epidermal growth factor receptor (EGFR) in oral squamous cell carcinoma in relation to proliferation, apoptosis, angiogenesis and lymphangiogenesis. *Head Neck Oncol* 2010; **2**:13.
9. Zhu X, Zhang F, Zhang W, He J, Zhao Y, Chen X. Prognostic role of epidermal growth factor receptor in head and neck cancer: A meta-analysis. *J Surg Oncol* 2013; **108**:387-97.
10. Vigneswaran N, Williams MD. Epidemiologic trends in head and neck cancer and aids in diagnosis. *Oral Maxillofac Surg Clin North Am* 2014; **26**:123-41.
11. Rubin Grandis J, Tweardy DJ, Melhem MF. Asynchronous modulation of transforming growth factor alpha and epidermal growth factor receptor protein expression in progression of premalignant lesions to head and neck squamous cell carcinoma. *Clin Cancer Res* 1998; **4**:13.
12. Shin DM, Ro JY, Hong WK, Hittelman WN. Dysregulation of epidermal growth factor receptor expression in premalignant lesions during head and neck tumorigenesis. *Cancer Res* 1994; **54**:3153.

13. Parkin DM, Pisani P, Ferlay J. Estimates of the worldwide incidence of 25 major cancers in 1990. *Int J Cancer* 1999; **80**:827-41.
14. Larizadeh MH, Damghani MA, Shabani M. Epidemiological characteristics of head and neck cancers in Southeast of Iran. *Iran J Cancer Prev* 2014; **7**:80-6.
15. Naz S, Salah K, Khurshid A, Hashmi AA, Faridi N. Head and neck squamous cell carcinoma - comparative evaluation of pathological parameters in young and old patients. *Asian Pac J Cancer Prev* 2015; **16**:4061-3.
16. Novin K, Ameri A, Faraji S, Torbati P, Mortazavi N. Head and neck squamous cell carcinoma in Iran: Clinico-pathological and treatment-related factors influencing survival. *Iran J Cancer Prev* 2015; **8**:e3842.
17. Slootweg PJ, Bolle CW, Koole R, Hordijk GJ. Cause of death in squamous cell carcinoma of the head and neck. An autopsy study on 31 patients. *J Craniomaxillofac Surg* 1992; **20**:225-7.
18. de Carvalho MB, Lenzi J, Lehn CN, Fava AS, Amar A, Kanda JL, et al. Clinical and epidemiological characteristics of squamous cell carcinoma of the oral cavity in women. *Rev Assoc Med Bras* 2001; **47**:208-14.
19. Parada C, Chai Y. Mandible and tongue development. *Curr Top Dev Biol* 2015; **115**:31-58.
20. Cho KJ, Khang SK, Lee SS, Koh JS, Chung JH, Lee YS, et al. Cancers of the upper aerodigestive tract in Korea. *J Korean Med Sci* 2002; **17**:18-22.
21. Andisheh-Tadbir A, Mehrabani D, Heydari ST. Epidemiology of squamous cell carcinoma of the oral cavity in Iran. *J Craniofac Surg* 2008; **19**:1699-702.
22. Effiom OA, Adeyemo WL, Omitola OG, Ajayi OF, Emmanuel MM, Gbotolorun OM. Oral squamous cell carcinoma: A clinicopathologic review of 233 cases in Lagos, Nigeria. *J Oral Maxillofac Surg* 2008; **66**:1595-9.
23. Roland NJ, Caslin AW, Nash J, Stell PM. Value of grading squamous cell carcinoma of the head and neck. *J Oral Maxillofac Pathol* 2014; **18**:183-8.
24. Maiti GP, Mondal P, Mukherjee N, Ghosh A, Ghosh S, Dey S, et al. Overexpression of EGFR in head and neck squamous cell carcinoma is associated with inactivation of SH3GL2 and CDC25A genes. *PLoS One* 2013; **8**:e63440.
25. Brunner K, Fischer CA, Driemel O, Hartmann A, Brockhoff G, Schwarz SEGFR (HER) family protein expression and cytogenetics in 219 squamous cell carcinomas of the upper respiratory tract: ERBB2 overexpression independent prediction of poor prognosis. *Anal Quant Cytol Histol* 2010; **32**:78-89.

