

# Accidental Phosphine Gas Poisoning with Fatal Myocardial Dysfunction in Two Families

Saleem Akhtar<sup>1</sup>, Arshalooz Rehman<sup>1</sup>, Surraya Bano<sup>2</sup> and Anwarul Haque<sup>1</sup>

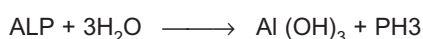
## ABSTRACT

Aluminum phosphide is commonly used as a rodenticide and insecticide and is one of the most fatal poisons. The active ingredient is Phosphine gas which inhibits cytochrome oxidase and cellular oxygen utilization. The clinical symptoms are due to multiorgan involvement including cardiac toxicity which is the most common cause of mortality. Severity of clinical manifestations depends upon the amount of the gas to which a person is exposed. There is no specific antidote available. High index of suspicion and early aggressive treatment is the key to success. We report 2 cases of aluminum phosphide toxicity in 2 families due to incidental exposure after fumigation.

**Key Words:** Aluminum phosphide. Cardiac dysfunction. Fumigation.

## INTRODUCTION

Aluminum phosphide, a very effective rodenticide and insecticide is commonly used to protect grains and tobacco stores during storage and shipment.<sup>1,2</sup> It is formulated either as a pellet or a tablet.<sup>1</sup> Upon exposure to water, it releases phosphine gas which is the active agent and has toxic potential. The chemical reaction responsible for this is as follows:



Phosphine gas (PH<sub>3</sub>) is responsible for these toxic effects of Aluminum Phosphide (ALP).<sup>1,3</sup> Phosphine is a colorless gas and typically odorless when pure. However, when it is mixed with other substances it has a fish or garlic odor. Phosphine gas is highly toxic to insects, burrowing pests, humans, and animals.<sup>1</sup> Clinical manifestations of phosphine toxicity depend upon the amount of gas to which the person is exposed. This is expressed as parts per million (ppm).<sup>4</sup> Cardiac toxicity is the most common cause of mortality in most of cases. There is no specific treatment of phosphine poisoning, and fatal outcome is common.<sup>5,6</sup> Occupational exposure can occur in industry workers. Aluminum phosphide (ALP) has been reported as a cause of suicidal exposure in adults and also accidental poisoning in children in India.<sup>5</sup> But there is no available data from Pakistan.

We report accidental inhalational exposure of 2 families after house fumigation with a fatal outcome.

## CASE REPORT

**Case 1:** A 5-member family (2 parents and 3 children aged 8, 5 and 3 years) living in a residential area of Karachi in Pakistan hired services of a fumigation agency for fumigation of their house. Company personnel drilled shallow holes in the house and placed some chemical in the holes. The exact nature of the chemical was not told to the family. Family members were advised to keep the home closed for few hours. Family had to go to attend a marriage; they went to attend the ceremony and returned late at night. They slept at night and early in the morning all the family members started having nausea and vomiting. Children were more seriously affected. They came to the hospital and were initially managed on the lines of food poisoning. However, the 8-year-child continued to deteriorate and developed tachycardia hypotension and metabolic acidosis and expired within few hours of arrival in the hospital before a definitive cause could be established.

Meanwhile the second child aged 5 years who was also sick was admitted to Pediatric Intensive Care Unit (PICU) and was managed on the lines of organophosphate poisoning as the exact nature of the fumigation agent was not known. He improved transiently in the PICU and was discharged 2 days later directly from PICU on parents' request. Within 24 hours he came back in the emergency room with progressively increasing respiratory distress. He was evaluated and was found to have severe myocardial dysfunction on echocardiogram and expired within 6 hours of PICU stay despite maximum supportive therapy.

Extra Corporeal Membrane Oxygenation (ECMO) service was not available in Pakistan at that time and the patient expired due to severe myocardial dysfunction. The fumigation agency was asked to provide the chemical used for chemical analysis and report conformed this to

*Department of Pediatrics and Child Health<sup>1</sup> / Emergency Medicine<sup>2</sup>, The Aga Khan University Hospital, Karachi.*

*Correspondence: Dr. Saleem Akhtar, Department of Pediatrics and Child Health, The Aga Khan University Hospital, Karachi.*

*E-mail: saleem.sadqani@aku.edu*

*Received: April 10, 2013; Accepted: February 10, 2015.*

be Aluminum Phosphide (ALP). The third child was fortunate and had mild cardiac dysfunction which recovered completely after 3 - 4 months of supportive cardiac treatment.

**Case 2:** A toddler aged 3 years and an infant aged 1 year were brought to the ER with complaints of vomiting and abdominal pain for the last 4 hours. They were all right few hours back. Family gave the history of fumigation one day prior to onset of symptoms. The protocol for fumigation was the same as described in the above case. The older child was sick and despite adequate fluid resuscitation continued to deteriorate. He was tachycardiac, tachypnoeic and developed metabolic acidosis despite fluid resuscitation. He was treated as sepsis and antibiotic coverage was added. He, however, continued to deteriorate. So his electrocardiogram (ECG) and echocardiogram and cardiac enzyme (Troponin I) were investigated. ECG showed sinus tachycardia and ST-T segment changed indicating cardiac injury. Echocardiogram showed severe cardiac dysfunction. His Troponin I was also increased. He was started on intravenous inotropes (dopamine and milrinone) and shifted to PICU. Within half an hour of being shifted to intensive care unit the patient went into ventricular fibrillations and expired despite attempted resuscitation. The other child was aggressively managed in the ER with inotropic support and was electively intubated in the ER. His work up also showed moderate myocardial dysfunction on echocardiogram, sinus tachycardia on ECG along with ST-T changes and elevated cardiac enzymes. With aggressive therapy he was stabilized and was discharged in a week time from intensive care unit. His myocardial function fully recovered in 3 months' time and at 1-year follow-up he is doing fine and is off supportive therapy.

## DISCUSSION

The death of these children was due to myocardial dysfunction secondary to phosphine inhalation as shown by decreased ventricular function, electrocardiographic abnormalities, and elevation in blood concentrations of Troponin and creatine kinase isoenzyme MB. Clinical findings reported by various authors in acute phosphine poisoning include headache, vomiting, cough, depressed mental status, pulmonary edema, hypotension, cardiac dysrhythmias, liver and kidney failure, and severe gastritis.<sup>7</sup> The children in these cases also presented with nausea and vomiting and later developed the clinical features of cardiovascular toxicity. The cardiovascular system toxicity of phosphine is quite varied and extensive. It ranges from mild hypotension to complete cardiovascular collapse and is the cause of mortality as is seen in these cases.<sup>5</sup> The exposed children in these cases also developed manifestations of cardiovascular collapse and could not be saved despite maximum available supportive treatment. Unintentional poisoning

from inhalation of phosphine gas is rare.<sup>8,9</sup> However, occasional occupational exposure and suicidal ingestions are reported. Occupational exposure limits for phosphine gas has been established. The National Institute for Occupational Safety and Health occupational exposure has established limits for phosphine gas at 0.3 ppm while levels equal to or more than 50 ppm are described as "immediately dangerous to life or health."<sup>1</sup> Mortality rate as high as 77% has been reported.<sup>9</sup>

Management of the patients affected with phosphine is mainly supportive as was done in these patients. There is no accepted specific treatment.<sup>3</sup> A variety of manoeuvres have been suggested as possibly improving outcome; including administration of magnesium, N-acetylcysteine, pralidoxime, or trimetazidine, as well a combination of insulin and glucose administration along with hyperventilation. Few case reports of use of vegetable oil and coconut oil has also been reported.<sup>10</sup> However, at present evidence is insufficient to advocate use of any of these therapies as a component of care.

Organophosphates are generally considered the most likely agent when history of fumigation is present. However, other agents should be considered especially when there is evidence of serious cardiovascular compromise along with history of fumigation.

## REFERENCES

1. Lemoine TJ, Schoolman K, Jackman G, Vernon DD. Unintentional fatal phosphine gas poisoning of a family. *Pediatr Emerg Care* 2011; **27**:869-71.
2. Proudfoot AT. Aluminum and zinc phosphide poisoning. *Clin Toxicol (Phila)* 2009; **47**:89-100.
3. Bogle RG, Theron P, Brooks P, Dargan PI, Redhead J. Aluminum phosphide poisoning. *Emerg Med J* 2006; **23**:e3.
4. Pepelko B, Seckar J, Harp PR, Kim JH, Gray D, Anderson EL. Worker exposure standard for phosphine gas. *Risk Anal* 2004; **24**:1201-13.
5. Shah V, Baxi S, Vyas T. Severe myocardial depression in a patient with aluminum phosphide poisoning: a clinical, electrocardiographical and histopathological correlation. *Indian J Crit Care Med* 2009; **13**:41-3.
6. Singh D, Jit I, Tyagi S. Changing trends in acute poisoning in Chandigarh zone: a 25-year autopsy experience from a tertiary care hospital in northern India. *Am J Forensic Med Pathol* 1999; **20**:203-10.
7. Singh S, Singh D, Wig N, Jit I, Sharma BK. Aluminum phosphide ingestion: a clinico-pathologic study. *J Toxicol Clin Toxicol* 1996; **34**:703-6.
8. Wilson R, Lovejoy FH, Jaeger RJ, Landrigan PL. Acute phosphine poisoning aboard a grain freighter. Epidemiologic, clinical, and pathological findings. *JAMA* 1980; **244**:148-50.
9. Sudakin DL. Occupational exposure to aluminum phosphide and phosphine gas? A suspected case report and review of the literature. *Hum Exp Toxicol* 2005; **24**:27-33.
10. Shadnia S, Rahimi M, Pajoumand A, Rasouli MH, Abdollahi M. Successful treatment of acute aluminum phosphide poisoning: possible benefit of coconut oil. *Hum Exp Toxicol* 2005; **24**:215-8.

