

Primary Posterior Mediastinum Hydatid Cyst

Mughis Uddin Ahmed¹, Ahmed Fathi Eid², Nadia Al-Hawashim³,
Mohammed Younus Sheikh² and Nearchos Yiannakou¹

ABSTRACT

Primary posterior mediastinal hydatid cyst is a serious health problem for the Mediterranean countries. We diagnosed a case of a 46-year-old female with a primary posterior mediastinum hydatid cyst on CT and MRI. It was provisionally identified as either a hydatid cyst or bronchogenic cyst or neuroenteric cyst. CT guided aspiration with 18 gauge needle confirmed as hydatid sand. This is very rare in this population but it should be kept in mind when one is looking at any cyst in the posterior mediastinum.

Key Words: *Hydatid cyst. Posterior mediastinum. Hydatid sand.*

INTRODUCTION

Echinococcus (E.) granulosus is also known as the *Taenia echinococcus*. Worldwide some areas were more affected like the Mediterranean (Turkey), the Middle East, South America, Africa, New Zealand, Russian Federation, Central Asia and Australia. There are four species of *Echinococcus*; *E. granulosus*, *E. multilocular*, *E. oligarthrus* and *E. vogeli*. The larval stage is present in intermediate host like sheep, pigs, cattle, horses, goats and man as a hydatid cyst. The adult form of this worm is present in a definite host like dogs, wolves, foxes, coyotes and jackals.¹⁻³

The most common site for hydatid cysts are the liver (70%), followed by lung (10 - 20%), brain (5%), spleen (2%), kidney (2%), female reproductive system (2%), femur (1%). Cysts are detected clinically and radiologically or by radiological procedures like plain X-ray, ultrasound, CT and MRI.⁴ They may create pressure or rupture, although they may be symptomless in some parts of the body. Casoni's test and other serological tests like complement fixation test, indirect haemagglutination assay, counter immune electrophoresis, enzyme linked immunosorbent assay, radio immuno assay, dot enzyme linked immunosorbent assay and indirect immuno fluorescent assay are used for immunologic diagnosis. Serology testing may give cross reactivity with cysticercosis, schistosomiasis, taeniasis and trichinosis. Direct microscopy and stained microscopy is also a useful method for diagnosis. Histopathology and cytology can also be used for diagnosis of this disease. Exploratory cyst puncture will help in diagnosis as well

as surgical removal by using formalin, silver nitrate or hypertonic saline injected to kill the scolices before removal. Aspirated fluid is centrifuged at 3000 rpm for 5 minutes, hydatid sand in suspension from which a drop can be taken directly on to glass slide with cover slip and also stained preparation seen under microscope.⁵⁻⁸

Best chemotherapy is Albendazole or Mebendazole which can be used before as well as after excision which will prevent recurrence of disease. The disease can be prevented by the treatment of infected dogs, reduction of dog population and prevention of dogs from eating the infected offals of domestic animals in the slaughter houses as well as proper disposal of dog's faeces.⁹

CASE REPORT

A 46-year-old Saudi lady from Eastern region (Al-Ahsa), known diabetic and hypertensive with abnormal kidney function, underwent renal transplant 5 years back. She had also been operated on for fibroadenoma of breast long ago. She was admitted to hospital for fever with chills, malaise, cough with dyspnoea and basal crepitation. A plain chest X-ray revealed widening of mediastinum, hilar shadows and consolidation of both lungs. Laboratory investigation showed high blood-urea-nitrogen and serum creatinine levels and mild eosinophilia. Later CT and MRI were done which resulted in differential diagnosis hydatid cyst, bronchogenic cyst and neuroenteric cyst (Figure 1 and 2). They were expecting enlargement of regional lymph node. Later on, CT guided aspiration of fluid was done with an 18 gauge needle and sent to laboratory, where it was diagnosed as hydatid sand (Figure 3 and 4). Echino antibody titer was also determined which was < 16 titer. No growth came from culture of aspirated material. This cyst was closed to vital structures of the mediastinum like superior and inferior vena cava, esophagus, recurrent nerve, pulmonary and sub-clavian arteries.

Since she was a high-risk patient, CT-guided scolical agent (hydrogen peroxide) instillation was used to

*Department of Microbiology¹ / Medical Imaging² / Pathology³,
King Abdulaziz Hospital (NGHA) Al-Ahsa, Saudi Arabia.*

*Correspondence: Prof. Mughis Uddin Ahmed, House No. 101,
Building 350, King Abdulaziz Hospital, (NGHA) Residence
Section Code (105), P. O. Box 2477, Al-Ahsa-31982, Saudi Arabia.
E-mail: drmughis@rediffmail.com*

Received: May 10, 2011; Accepted: April 05, 2013.

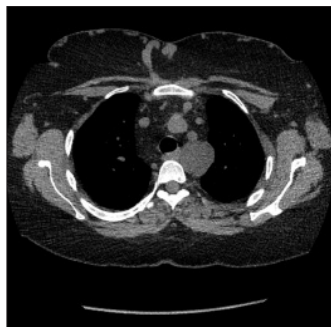


Figure 1: CT non-contrast study of upper mediastinum shows well defined slightly lobulated cystic structure with density 10Hu posterior to left subclavian artery.

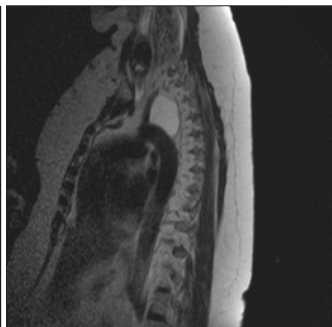


Figure 2: Sagittal T2W MRI of superior mediastinum with well defined cystic lesion of high signal just posterior to left subclavian artery and superior to arch of aorta opposite T3-T4 level about 37 x 26 mm in size.

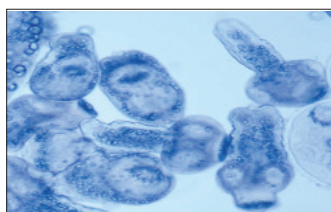


Figure 3: Hydatid sand.

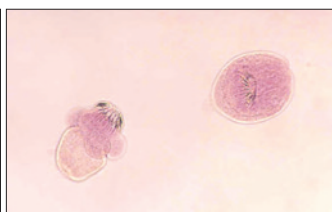


Figure 4: Hydatid sand - a close-up view.

prevent dissemination of parasite and all fluid present in cyst was aspirated. Follow-up CT without contrast was done and the size of previously seen cyst was found to be markedly reduced. This patient was discharged on 14 mg/kg/day of mebendazole for 6 months with liver function tests every month. The CT and MRI done at the conclusion of treatment were without any cyst and the remaining tissue size is also decreased in size to minimum.

DISCUSSION

An intrathoracic but extrapulmonary location of hydatid cyst is very rare and represents less than 0.1% of all localizations. The hydatid cyst of posterior mediastinum is very rare, rather an exceptional site. This case of posterior mediastinum hydatid cyst was diagnosed as an accidental find after a CT guided aspiration of fluid with hydatid sand. Mediastinal hydatid disease with unusual presentation has been reported by Mitra *et al.*, West Bengal, in 2010. A case of primary hydatid disease leading to popliteal artery hydatid cyst embolization was reported by Hakeem *et al.*, from Kashmir, India 2009.^{6,8}

In a study by Eroglu *et al.* from Turkey, 2.6% of those with intrathoracic hydatid cysts had mediastinal hydatid cyst.² Primary hydatid cysts of the mediastinum were

reported from rural area of Turkey by Glu *et al.*, 2002.² Giant primary mediastinal hydatid cyst causing Horner's syndrome was also reported.⁷

Primary hydatid cyst of the posterior mediastinum was diagnosed by Kabiri *et al.*, from Rabat, Morocco 2007 and 7 cases of mediastinal cyst were reported which comprised of 6 males and one female patient.^{3,5}

Pulmonary hydatid cyst was reported by Mallick *et al.*, from Riyadh, Saudi Arabia but it was not a primary posterior mediastinal hydatid cyst.⁹

Hydatid cyst of the posterior mediastinum although is a very rare condition, it should be considered in differential diagnosis of mediastinal cystic lesions particularly in endemic areas. Confirmation of diagnosis can be done by parasitologist by the presence of hydatid sand in the aspirated fluid. In case a surgeon wanted to plan the surgery he can coordinate with radiologist and parasitologist. CT guided aspiration of fluid should be sent to microbiology department and the result can be provided within 10 - 15 minutes which can help surgeon excised complete cyst. Treatment with scolicedal agent and mebendazole for 6 months is found to be good option in high-risk patients.

REFERENCES

1. Rezakhaniha B, Sirosbakht S. Coincidental hydatid cyst of skin and kidney: a very rare case report. *Iranian J Pathol* 2010; **5**:47-50.
2. Eroglu A, Kurkcuoglu C, Karaoglanoglu N, Tekinbas C, Kaynar H and Onbas O. Primary hydatid cysts of the mediastinum. *Eur J Cardiothorac Surg* 2002; **22**:599-601.
3. Kabiri EH, Zidane A, Atoini F, Arsalane A, Bellamari H. Primary hydatid cyst of the posterior mediastinum. *Asian Cardiovasc Thorac Ann* 2007; **15**:60-2.
4. Marcos FG, Popovsky S, Osorio ML. Hydatid cyst of the mediastinum. *Dis Chest* 1969; **56**:160-2.
5. Traibi A, Atoini F, Zidane A, Arsalane A, Kabiri E. Mediastinal hydatid cyst. *J Chin Med Assoc* 2010; **73**:3-7.
6. Mitra S, Kundu S, Das S, Mukherjee S. Mediastinal hydatid disease: an unusual presentation. *Indian J Chest Dis Allied Sci* 2010; **52**:245-7.
7. Sirmali M, Gezer S, Kaya S. Giant primary mediastinal hydatid cyst causing horners syndrome: report of a case. *Acta Chir Belg* 200; **105**:221-3.
8. Hakeem A, Shafi H, Gojwari TA, Rasool S, Ahmad M. Primary mediastinal hydatid disease leading to popliteal artery hydatid cyst embolization. *Ann Saudi Med* 2009; **29**:407-9.
9. Mallick MS, Al-Qahtani A, Al-Saadi MM, Al-Boukai AA. Thoracoscopic treatment of pulmonary hydatid cyst in a child. *J Pediatr Surg* 2005; **40**:e35-7.

.....☆.....