

Treatment Updates Regarding Anaplastic Oligodendroglioma and Anaplastic Oligoastrocytoma

Khurshid Ahmed Khan, Ahmed Nadeem Abbasi and Nasir Ali

ABSTRACT

Anaplastic Oligodendroglioma / Anaplastic Oligoastrocytoma (AO/AOA) is a WHO Grade-III primary brain tumor. These tumors comprise about 5 - 10% of all gliomas, which make them the third most common primary brain tumors after glioblastoma multiforme and astrocytomas. For many years standard of treatment remained Maximum Safe Resection (MSR) followed by Radiotherapy (RT). These tumors have also been known to be sensitive to alkylator-based chemotherapy particularly the subset having 1p/19q co-deletion signature. There is robust data showing that these tumors are responsive to chemotherapy in recurrent or progressive setting. Recently, up front chemotherapy has been added to standard post-surgery RT. It has been found that subset of AO/AOA having 1p/19q co-deletion responded very well to the addition of chemotherapy. This substantial benefit in terms of median Overall Survival (OS) and median Progression Free Survival (PFS) have intrigued the personalized treatment of AO/AOA on the basis of molecular signature markers.

Key Words: *Anaplastic oligodendroglioma. Brain tumors. 1p/19q co-deletion. Oligoastrocytoma.*

INTRODUCTION

American Cancer Society has estimated the incidence of adult Central Nervous System (CNS) tumors in the year 2013 as 23,130 and deaths of 14,080 in United States of America.¹ Primary CNS tumors are comprised of gliomas predominantly. Brain tumors account for 85% to 90% of all primary central nervous system tumors.²

Oligodendrogliomas are tumors of supporting oligodendrocytes. Though they are uncommon, yet comprise the third most common primary brain glial tumor after glioblastoma multiforme and astrocytomas. Oligodendrogliomas constitute between 5 - 10% of all brain gliomas.^{3,4}

There is a convincing evidence that the incidence of oligodendrogliomas are increasing due to better diagnostic accuracy. It is believed that various gliomas reported in the past were in fact oligodendrogliomas.⁵⁻⁸ It has been shown that various mixed gliomas with oligodendroglial components like anaplastic oligoastrocytomas, behave similarly as pure oligodendrogliomas.⁹

Oligodendroglial tumors are frequently encountered in the fourth to sixth decades, with an average age at diagnosis of approximately 45 years. Median overall survival for Grade-II and Grade-III tumors is 10 years and 3 - 5 years, respectively.^{5,10,11}

World Health Organization (WHO) has classified oligodendrogliomas into low grade well-differentiated

oligodendrogliomas and oligoastrocytomas (WHO grade-II), and Anaplastic Oligodendrogliomas (AOs) and Anaplastic Oligoastrocytomas (AOAs) (WHO grade-III). High-grade tumors demonstrate increased cellularity, show high mitotic activity, nuclear atypia, vascular proliferation, and frequent tumor necrosis.⁵

Molecular Markers: Allelic co-deletion of 1p/19q in oligodendrogliomas is a very common phenomenon. About 50 - 60% of the tumors demonstrate this molecular signature on paraffin-embedded tissues. Co-deleted tumors are shown to be more sensitive to alkylator-based chemotherapies.¹²⁻¹⁴ Other molecular markers like mutation of Isocitrate Dehydrogenase (IDH-1 and 2), as well as O,6-Methylguanine-DNA Methyltransferase (MGMT) promoter methylation are considered as good prognostic markers in Oligodendrogliomas.¹⁵⁻¹⁸

Computed Tomography (CT Scan): Typically on CT scan, 60 - 70% of oligodendrogliomas appear hypodense or isodense, with poor contrast enhancement. Some degree of contrast enhancement has been reported to occur in 24 - 66% of cases. Peri-tumor edema is usually mild or absent. A rare intraventricular oligodendrogliomas however, have a typical hyperdense appearance. There are frequent demonstrable cystic changes and hemorrhage in the tumor on CT scan. Oligodendroglioma is very typical for developing intra-tumoral calcifications, which may appear as coarse, punctate or linear on CT scan.^{8,19,20}

Magnetic Resonance Imaging (MRI): MRI is the investigation of choice in neuroimaging. Oligodendroglioma is typically hypointense on T1-weighted images and hyperintense on T2-weighted images, often well demarcated with little peri-tumoral edema (Figure 1).

Department of Oncology, The Aga Khan University Hospital, Karachi.

Correspondence: Dr. Khurshid Ahmed Khan, E1, Pak Tameer Plaza, Gulshan-e-Iqbal, Block-14, Karachi.

E-mail: khurshid.khan@aku.edu

Received: April 19, 2013; Accepted: June 06, 2014.

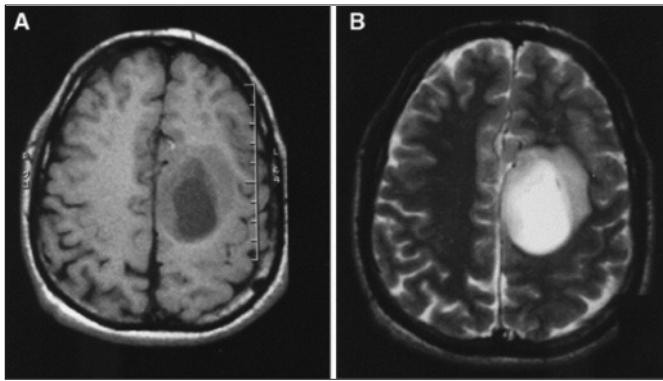


Figure 1: Axial MR images of a cystic tumor, found to be an anaplastic oligodendroglioma. (A) Unenhanced T1-weighted image, showing varying degrees of hypo intensity. (B) T2-weighted image showing hyper intensity, especially of the central cyst.

MRI is more sensitive than CT scan for demonstrating brain matter abnormalities and enhancement. These tumors are heterogeneous in appearance on imaging due to the presence of varying degrees of intra-tumoral hemorrhage, areas of cystic degeneration, and/or calcifications.^{8,21,22}

No correlation has been found between pattern of contrast enhancement and 1p/19q co-deletion status. However, tumors with 1p/19q co-deletion are associated with infiltrative borders on T1-weighted MRI images and presence of intra-tumor calcification, whereas tumors having 1p/19q non co-deletion typically have a distinct border and a uniform signal on T1/T2-weighted images.^{6,8,23} It is important, however, to emphasize that none of these imaging findings are specific and only tissue diagnosis will settle the issue.

It is worth mentioning that post-surgical MRI should be done within 72 hours for documentation of extent of the resection. Otherwise, four weeks post-surgery imaging will be the imaging timeline.

Positron Emission Tomography (PET) Scan: In general, brain PET scan is a functional imaging modality that can provide quantitative information regarding glucose metabolism, blood flow, and amino acid metabolism.

Positron-emitting radio-isotope Carbon-11-Methionine (¹¹C-MET) PET has been reported to be useful in discriminating oligodendroglioma patients being followed for residual / recurrent tumor as opposed to radiotherapy-related necrosis. Functional imaging is also invaluable in determining the degree of malignancy (standard uptake values), guiding surgeons to obtain biopsy from most malignant area, and monitoring conversion to higher grades.²⁴⁻²⁷

In future, PET/MRI fusion will be an invaluable tool for more accurate treatment planning in state of the art radiotherapy.

Literature Search Strategy: Literature was reviewed regarding the standard therapy manually using the

library and online through Index Medicus, MEDLINE/ PubMed and EMBASE database for the literature published till August 31, 2013. Literature search included randomized control trial, meta-analysis, systemic review, retrospective case series, practice guidelines and review articles. MeSH keywords used for the search included brain tumors, oligodendroglioma, oligoastrocytoma, management of brain neoplasm, chemotherapy and radiation therapy.

The standard of care for AO/AOA is Maximal Safe Resection (MSR) followed by adjuvant radiotherapy (RT) and chemotherapy.

Surgery: Surgery is the most important component of overall management of gliomas. Surgical goal for oligodendroglioma should be gross total removal, if the tumor can be safely resected.²⁸⁻³² Evidence has indicated that a more complete resection of tumor is associated with better survival.³³⁻³⁶

It is absolutely essential to obtain tissue for accurate histopathological diagnosis. Tumor resection facilitates in reducing the mass effect and improving related symptoms and neurological deficits. Gliomas are frequently heterogeneous in grade and histology, tumor resection may also reduce sampling errors that may occur with biopsy alone.^{28,30,36}

Radiotherapy and Chemotherapy: Radiotherapy has long been a standard of care for these gliomas after surgery. Randomized controlled trials have clearly demonstrated the benefits of adding RT.³⁷⁻³⁹

It is known for about more than two decades that these tumors are sensitive to a combination of chemotherapy drugs consisting of Procarbazine, Lomustine and Vincristine (PCV) chemotherapy when responses were documented for small series of patients with recurrent tumors and later established by prospective studies.^{40,41} These findings were the backbone for conducting Randomized Controlled Trials (RCT) in AO/AOAs to study the role of chemotherapy in the adjuvant setting.

Two latest RCTs have shown that addition of chemotherapy to the standard treatment of surgery and radiotherapy has dramatic results in the outcomes of these tumors. Radiation Therapy Oncology Group (RTOG) 9402 trial randomized 291 eligible AO/AOAs patients into two arms after surgery. Experimental arm comprised of 148 patients who received 04 cycles of dose-intense PCV chemotherapy followed by RT. Control arm had 143 patients who received standard adjuvant RT. Radiation doses in both arms were standardized as 59.4 Gy in 33 fractions of 1.8 Gy, 5 days a week, over 6.5 weeks. Both arms were well balanced in terms of age, gender, performance status, extent of resection and 1p/19q co-deletion status.⁴² Results for the entire cohort revealed that median Overall Survival (OS) was the same for both arms: 4.6 years for

chemotherapy + RT and 4.7 years for RT, Hazard Ratio (HR) of 0.79 [95% Confidence Interval (CI) 0.6 - 1.04, $p=0.10$]. However, patients with 1p/19q co-deletions lived twice as long with PCV chemotherapy followed by radiation as opposed to radiation alone (median OS 14.7 years versus 7.3 years, respectively [HR 0.59 ($p = .03$)]. Median overall survivals of 2.6 years and 2.7 years were not significantly different in patients without such deletions in the experimental and controlled arms [HR 0.85; 95% CI, 0.58 - 1.23 ($p = .39$)].

European Organization for Research and Treatment of Cancers (EORTC) 26951 trial randomized 368 patients of AO and AOA post-surgery, to receive either 59.4 Gy radiotherapy alone or radiotherapy followed by six cycles of PCV chemotherapy.⁴³ The results of this trial are not different from RTOG 9402 study. A total of 80 patients out of 316 were found to have 1p/19q co-deleted tumors. In these patients with the 1p/19q co-deletions, median Progression Free Survival (PFS) was significantly prolonged with the addition of PCV chemotherapy. Median OS was 112 months with radiation alone, but had not been reached in RT and chemotherapy arm for co-deleted tumors at the time of publication. This translated into a dramatic 44% reduction in risk of Death Rates (HR = 0.56). Among those patients having 1p/19q non co-deletions, median OS was not different significantly.

DISCUSSION

Anaplastic oligodendrogliomas/anaplastic oligo-astrocytomas can be divided into two groups on the basis of molecular signature of 1p/19q co-deletion which has consistently shown to be a prognostic and predictive marker in AO/AOAs.^{12,42-44} Long-term follow-up from the two large randomized trials have consistently shown that patients with newly diagnosed AO/AOAs have dramatically longer OS if PCV chemotherapy is added to standard radiation therapy. The benefit was greatest among patients with tumors that contain the signature chromosome 1p and 19q deletions, which occurs in about 50 - 60% of patients with this type of glioma.¹²⁻¹⁴ Patients with the co-deletions experienced a 44% reduction in the risk of death, compared with a 25% risk reduction among all 368 patients in the European Organization for Research and Treatment of Cancer (EORTC) 26951 trial.⁴² These results have opened the venue for personalized medicine, not based on histology but the molecular signatures. Other studies have also proven the prognostic significance of molecular markers like 1p/19q and IDH 1/2 status.⁹

These two recently reported trials have used PCV chemotherapy which is an old and a very toxic regimen. In fact about 33 - 38% of patients in the two trials were not able to complete their chemotherapies due to PCV-induced grade III and IV hematologic toxicities.^{42,43} The

most important question now is to use more toxic PCV regimen or temozolomide which is significantly less toxic, oral alkylating agent chemotherapy in anaplastic oligodendroglioma with 1p/19q co-deletion.

Grade-IV gliomas (Glioblastoma Multiforme) have shown significant survival advantage with the use of concurrent and adjuvant Temozolomide with radiation.⁴⁵ However, there is no head to head trial in oligodendrogliomas to determine whether molecular signature in AO/AOAs, predicting response to chemotherapy is a class effect or is unique to PCV chemotherapy.

The German NOA-4 trial has shown that PCV was not superior to Temozolomide for Grade-III gliomas.⁴⁶ The critique, however, is that there is limited follow-up with only 43% of patients have reached the primary end point of Time to Treatment Failure (TTF). Also, it was an underpowered trial to reliably show any difference between the two regimens.

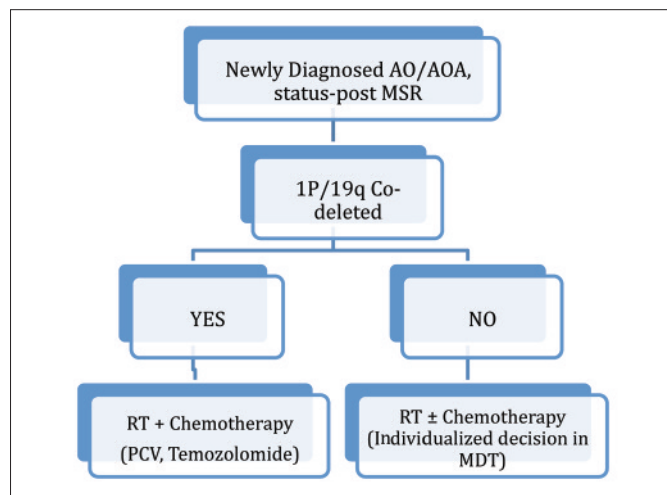
Studies have shown that 1p/19q co-deleted AO/AOAs who receive adjuvant RT and on progression receive PCV chemotherapy, have response duration ranging from 12 to 24 months.⁴⁷⁻⁴⁹ Hence, both RTOG 9402 and EORTC 26951 studies have shown major improvement in outcome for 1p/19q co-deleted tumors when RT + PCV chemotherapy was employed in the adjuvant setting up front as opposed to adding PCV on progression.

Therefore, it is evidence-based to conclude that 1p/19q co-deleted AO/AOAs should now be treated with adjuvant RT + chemotherapy. PCV and temozolomide are not being compared head to head in a large randomized trial, assuming that combined chemo-irradiation with temozolomide provides equivalent results compared with RT+PCV which remains, however, a leap of faith.

Another important question is whether 1p/19q non co-deleted tumors should be treated differently? In both trials (RTOG 9402 and EORTC 26951), no survival benefit was identified with the addition of PCV chemotherapy to RT. However, a meaningful analysis will require a large sample size. In an ongoing current trial CATNON (Concurrent and Adjuvant Temozolomide chemotherapy in 1p/19q non co-deleted anaplastic glioma) will be able to answer this question. Till the results of such trial are published, addition of chemotherapy to standard postoperative RT in AO/AOAs should be individualized after discussion in a multi-disciplinary tumor boards.

CONCLUSION

Anaplastic Oligodendrogliomas/Anaplastic Oligoastrocytomas (AO/AOAs) should be stratified on the basis of molecular signature 1p/19q co-deletion status. Post-surgical decision of adding chemotherapy to standard



RT should be the standard of care in co-deleted tumors. Until the results of randomized-controlled trials like CANTON, non-co-deleted tumors should be discussed in multi-disciplinary tumor boards for the individualized decision of adding chemotherapy to RT.

A simplified treatment algorithm for newly diagnosed AO/AOAs postsurgery is given below:

REFERENCES

1. American Cancer Society. Cancer facts and figures 2013. Atlanta, GA: American Cancer Society; 2013.
2. Mehta M, Vogelbaum MA, Chang S, editors. DeVita, Hellman, and Rosenberg's cancer: principles and practice of oncology. 9th ed. Philadelphia, PA: Elsevier; 2011.
3. Central Brain Tumor Registry of the US. Statistical report: primary brain tumors in the United States, 1998-2002. Hinsdale, IL: Central Brain Tumor Registry of the US; 2005.
4. Ahmad Z, Arshad H, Hasan SH, Fatima S, Idrees R, Aftab K, et al. CNS neoplasms in Pakistan, a pathological perspective. *Asian Pac J Cancer Prev* 2011; **12**:317-21.
5. Louis DN, Ohgaki H, Wiestler OD, Cavenee WK, Burger PC, Jouvet A, et al. The 2007 WHO classification of tumours of the central nervous system. *Acta Neuropathologica* 2007; **114**: 97-109.
6. Armed Forces Institute of Pathology, Burger PC, Scheithauer BW, National Research Council. Subcommittee on Oligodendrogliomas, Universities Associated for Education in Pathology. Atlas of tumor pathology. Armed Forces Institute of Pathology; 2011.
7. Engelhard HH, Stelea A, Cochran EJ. Oligodendroglioma: pathology and molecular biology. *Surg Neurol* 2002; **58**:111-7; discussion 7.
8. Dumas-Duport C, Varlet P, Tucker ML, Beuvon F, Cervera P, Chodkiewicz JP. Oligodendrogliomas. Part I: Patterns of growth, histological diagnosis, clinical and imaging correlations: a study of 153 cases. *J Neurooncol* 1997; **34**: 37-59.
9. Jiang H, Ren X, Cui X, Wang J, Jia W, Zhou Z, et al. 1p/19q codeletion and IDH1/2 mutation identified a subtype of anaplastic oligoastrocytomas with prognosis as favorable as anaplastic oligodendrogliomas. *Neuro Oncol* 2013; **15**:775-82.

10. Coons SW, Johnson PC, Scheithauer BW, Yates AJ, Pearl DK. Improving diagnostic accuracy and inter-observer concordance in the classification and grading of primary gliomas. *Cancer* 1997; **79**:1381-93.
11. Fisher JL, Schwartzbaum JA, Wrensch M, Wiemels JL. Epidemiology of brain tumors. *Neurol Clin* 2007; **25**:867-90, vii.
12. Ramirez C, Bowman C, Maurage CA, Dubois F, Blond S, Porchet N, et al. Loss of 1p, 19q, and 10q heterozygosity prospectively predicts prognosis of oligodendroglial tumors--towards individualized tumor treatment? *Neuro Oncol* 2010; **12**:490-9.
13. Xiong J, Liu Y, Wang Y, Ke RH, Mao Y, Ye ZR. Chromosome 1p/19q status combined with expression of p53 protein improves the diagnostic and prognostic evaluation of oligodendrogliomas. *Chin Med J (Engl)* 2011; **123**:3566-73.
14. Alentorn A, Sanson M, Idbaih A. Oligodendrogliomas: new insights from the genetics and perspectives. *Curr Opin Oncol* 2012; **24**:687-93.
15. van den Bent MJ, Dubbink HJ, Sanson M, van der Lee-Haarloo CR, Hegi M, Jeuken JW, et al. MGMT promoter methylation is prognostic but not predictive for outcome to adjuvant PCV chemotherapy in anaplastic oligodendroglial tumors: a report from EORTC Brain Tumor Group Study 26951. *J Clin Oncol* 2009; **27**:5881-6.
16. van den Bent MJ, Gravendeel LA, Gorlia T, Kros JM, Lapre L, Wesseling P, et al. A hypermethylated phenotype is a better predictor of survival than MGMT methylation in anaplastic oligodendroglial brain tumors: a report from EORTC study 26951. *Clin Cancer Res* 2011; **17**:7148-55.
17. Yan H, Parsons DW, Jin G, McLendon R, Rasheed BA, Yuan W, et al. IDH1 and IDH2 mutations in gliomas. *N Engl J Med* 2009; **360**:765-73.
18. van den Bent MJ, Dubbink HJ, Marie Y, Brandes AA, Taphoorn MJ, Wesseling P, et al. IDH1 and IDH2 mutations are prognostic but not predictive for outcome in anaplastic oligodendroglial tumors: a report of the European Organization for Research and Treatment of Cancer Brain Tumour Group. *Clin Cancer Res* 2010; **16**:1597-604.
19. Vonofakos D, Marcu H, Hacker H. Oligodendrogliomas: CT patterns with emphasis on features indicating malignancy. *J Comput Assist Tomogr* 1979; **3**:783-8.
20. Dolinskas CA, Simeone FA. CT characteristics of intraventricular oligodendrogliomas. *AJNR Am J Neuroradiol* 1987; **8**:1077-82.
21. Lee C, Duncan VW, Young AB. Magnetic resonance features of the enigmatic oligodendroglioma. *Invest Radiol* 1998; **33**: 222-31.
22. Diabira S, Rousset MC, Gamelin E, Soulier P, Jadaud E, Menei P. PCV chemotherapy for oligodendroglioma: response analyzed on T2 weighted-MRI. *J Neurooncol* 2001; **55**:45-50.
23. Carvalho Filho A, Salame JM. [Oligodendroglioma of the cerebellopontine angle: 16 years' course. Review of the literature and considerations on the pathology]. *Arq Neuropsiquiatr* 1989; **47**:241-7.
24. Derlon JM, Chapon F, Noel MH, Khouri S, Benali K, Petit-Taboue MC, et al. Non-invasive grading of oligodendrogliomas: correlation between *in vivo* metabolic pattern and histopathology. *Eur J Nucl Med* 2000; **27**:778-87.
25. Derlon JM, Petit-Taboue MC, Chapon F, Beaudouin V, Noel

- MH, Creveuil C, *et al.* The *in vivo* metabolic pattern of low-grade brain gliomas: a positron emission tomographic study using 18F-fluorodeoxyglucose and 11C-L-methylmethionine. *Neurosurgery* 1997; **40**:276-87; discussion 87-8.
26. Thiel A, Pietrzyk U, Sturm V, Herholz K, Hovels M, Schroder R. Enhanced accuracy in differential diagnosis of radiation necrosis by positron emission tomography-magnetic resonance imaging coregistration: technical case report. *Neurosurgery* 2000; **46**:232-4.
 27. Viader F, Derlon JM, Petit-Taboue MC, Shishido F, Hubert P, Houtteville JP, *et al.* Recurrent oligodendroglioma diagnosed with 11C-L-methionine and PET: a case report. *Eur Neurol* 1993; **33**:248-51.
 28. Allam A, Radwi A, El Weshi A, Hassounah M. Oligodendroglioma: an analysis of prognostic factors and treatment results. *Am J Clin Oncol* 2000; **23**:170-5.
 29. Shimizu KT, Tran LM, Mark RJ, Selch MT. Management of oligodendrogliomas. *Radiology* 1993; **186**:569-72.
 30. Fortin D, Cairncross GJ, Hammond RR. Oligodendroglioma: an appraisal of recent data pertaining to diagnosis and treatment. *Neurosurgery* 1999; **45**:1279-91; discussion 191.
 31. Sakata K, Hareyama M, Komae T, Shirato H, Watanabe O, Watarai J, *et al.* Supratentorial astrocytomas and oligodendrogliomas treated in the MRI era. *Jpn J Clin Oncol* 2001; **31**:240-5.
 32. Jeremic B, Shibamoto Y, Grujicic D, Milicic B, Stojanovic M, Nikolic N, *et al.* Combined treatment modality for anaplastic oligodendroglioma: a phase II study. *J Neurooncol* 1999; **43**:179-85.
 33. Dehghani F, Schachenmayr W, Laun A, Korf HW. Prognostic implication of histopathological, immunohistochemical and clinical features of oligodendrogliomas: a study of 89 cases. *Acta Neuropathol* 1998; **95**:493-504.
 34. Kros JM, Pieterman H, van Eden CG, Avezaat CJ. Oligodendroglioma: the Rotterdam-Dijkzigt experience. *Neurosurgery* 1994; **34**:959-66; discussion 66.
 35. Olson JD, Riedel E, DeAngelis LM. Long-term outcome of low-grade oligodendroglioma and mixed glioma. *Neurology* 2000; **54**:1442-8.
 36. Schiffer D, Dutto A, Cavalla P, Bosone I, Chio A, Villani R, *et al.* Prognostic factors in oligodendroglioma. *Can J Neurol Sci* 1997; **24**:313-9.
 37. Gannett DE, Wisbeck WM, Silbergeld DL, Berger MS. The role of postoperative irradiation in the treatment of oligodendroglioma. *Int J Radiat Oncol Biol Phys* 1994; **30**:567-73.
 38. Wallner KE, Gonzales M, Sheline GE. Treatment of oligodendrogliomas with or without postoperative irradiation. *J Neurosurg* 1988; **68**:684-8.
 39. Bullard DE, Rawlings CE, 3rd, Phillips B, Cox EB, Schold SC, Jr., Burger P, *et al.* Oligodendroglioma. An analysis of the value of radiation therapy. *Cancer* 1987; **60**:2179-88.
 40. Cairncross G, Macdonald D, Ludwin S, Lee D, Cascino T, Buckner J, *et al.* Chemotherapy for anaplastic oligodendroglioma. National Cancer Institute of Canada Clinical Trials Group. *J Clin Oncol* 1994; **12**:2013-21.
 41. van den Bent MJ, Kros JM, Heimans JJ, Pronk LC, van Groeningen CJ, Krouwer HG, *et al.* Response rate and prognostic factors of recurrent oligodendroglioma treated with procarbazine, CCNU, and vincristine chemotherapy. Dutch Neuro-oncology Group. *Neurology* 1998; **51**:1140-5.
 42. Cairncross G, Wang M, Shaw E, Jenkins R, Brachman D, Buckner J, *et al.* Phase III trial of chemoradiotherapy for anaplastic oligodendroglioma: long-term results of RTOG 9402. *J Clin Oncol* 2013; **31**:337-43.
 43. Erdem-Eraslan L, Gravendeel LA, de Rooi J, Eilers PH, Idbaih A, Spliet WG, *et al.* Intrinsic molecular subtypes of glioma are prognostic and predict benefit from adjuvant procarbazine, lomustine, and vincristine chemotherapy in combination with other prognostic factors in anaplastic oligodendroglial brain tumors: a report from EORTC study 26951. *J Clin Oncol* 2012; **31**:328-36.
 44. Thiessen B, Maguire JA, McNeil K, Huntsman D, Martin MA, Horsman D. Loss of heterozygosity for loci on chromosome arms 1p and 10q in oligodendroglial tumors: relationship to outcome and chemosensitivity. *J Neurooncol* 2003; **64**:271-8.
 45. Stupp R, Mason WP, van den Bent MJ, Weller M, Fisher B, Taphoorn MJ, *et al.* Radiotherapy plus concomitant and adjuvant temozolomide for glioblastoma. *N Engl J Med* 2005; **352**:987-96.
 46. Wick W, Hartmann C, Engel C, Stoffels M, Felsberg J, Stockhammer F, *et al.* NOA-04 randomized phase III trial of sequential radiochemotherapy of anaplastic glioma with procarbazine, lomustine, and vincristine or temozolomide. *J Clin Oncol* 2009; **27**:5874-80.
 47. Brandes AA, Tosoni A, Vastola F, Pasetto LM, Coria B, Danielli D, *et al.* Efficacy and feasibility of standard procarbazine, lomustine, and vincristine chemotherapy in anaplastic oligodendroglioma and oligoastrocytoma recurrent after radiotherapy. A phase-II study. *Cancer* 2004; **101**:2079-85.
 48. Cairncross JG, Ueki K, Zlatescu MC, Lisle DK, Finkelstein DM, Hammond RR, *et al.* Specific genetic predictors of chemotherapeutic response and survival in patients with anaplastic oligodendrogliomas. *J Natl Cancer Inst* 1998; **90**:1473-9.
 49. Kouwenhoven MC, Kros JM, French PJ, Biemond-ter Stege EM, Graveland WJ, Taphoorn MJ, *et al.* 1p/19q loss within oligodendroglioma is predictive for response to first line temozolomide but not to salvage treatment. *Eur J Cancer* 2006; **42**:2499-503.

