

Should We Routinely Expose Recurrent Laryngeal Nerve(s) During Thyroid Surgery?

Maqbool Ahmed¹, Aurangzeb¹, Safdar Abbas³, Muhammad Boota², Muhammad Ashfaq⁴,
Asif Zaman Rashid¹, Muhammad Azhar Qureshi¹ and Nauman Iqbal¹

ABSTRACT

Objective: To compare the frequency of recurrent laryngeal nerve(s) (RLNs) palsy after various thyroid procedures with and without identification of recurrent laryngeal nerve during the operation.

Study Design: Randomized controlled trial.

Place and Duration of Study: Department of Surgery, Military Hospital, Rawalpindi, from August 2008 to April 2010.

Methodology: Patients undergoing indirect laryngoscopy with normal vocal cords and those with carcinoma and re-do surgery having normal vocal cord were included in the study. Patients with hoarseness of voice, abnormal vocal cord movements and with solitary nodule in the isthmus were excluded. These patients were randomly divided into 2 groups of 50 each using random number tables. RLN was identified by exposing the inferior thyroid artery and traced along its entire course in group-A. Whereas, in group-B, nerves were not identified during the operations. Immediate postoperative direct laryngoscopy was performed by a surgeon with the help of an anaesthesiologist for the assessment of vocal cords. Patients with persistent hoarseness of voice were followed-up with indirect laryngoscopy at 3 and 6 months.

Results: Temporary unilateral recurrent laryngeal nerve palsies occurred in 2 (4%) patients in group-A where the voice and cord movements returned to normal in 6 months. In group-B, it occurred in 8 (16%) patients, 2 bilateral (4%) injuries requiring tracheostomy and 6 unilateral injuries (12%). Among the 2 bilateral recurrent laryngeal nerve injuries, the tracheostomy was removed in one case after 6 months with persistent hoarseness of voice but no respiratory difficulty during routine activities. Tracheostomy was permanent in the other case. Among the 6 cases of unilateral nerve injuries, the voice improved considerably in 4 cases within 6 months but in 2 cases hoarseness persisted even after 6 months. Frequency of recurrent laryngeal nerve palsies was significantly lower in group-A as compared to group-B ($p = 0.046$).

Conclusion: For safe thyroid surgery, recurrent laryngeal nerve(s) should be routinely exposed in its entire course.

Key words: Recurrent laryngeal nerve. Identification. Thyroid surgery.

INTRODUCTION

Recurrent laryngeal nerve (RLN) paralysis is a common and serious complication of thyroid surgery.¹ Few consultants routinely expose recurrent laryngeal nerves in every case while majority do not expose despite recommendations in various recent studies,² arguing that dissection for nerve exposure can lead to nerve damage.

Injury to the RLN can result from oedema, neuropraxia resulting from excessive stretching, complete or partial transection, contusion, crushing, clamping, burn, ligation or from compromised blood supply. An RLN injury results in true vocal fold paresis or paralysis which may

be unilateral or bilateral and may be temporary or permanent. If both the recurrent laryngeal nerves are damaged, it results in permanent tracheostomy and makes life of such patients miserable. Temporary palsy varies from 2.9% to over 10% whereas permanent nerve palsy occurs in 0 – 2.1%, with an average of approximately 0.5 – 1%. The right sided nerve is at a higher risk due to its wide anatomical variation as compared to the left one.³ Temporary palsy usually recovers within 6 months and anything persisting beyond 6 months is considered as permanent palsy. Other complications after the RLN injury may involve breathing difficulty, dysphagia and occasionally aspiration pneumonia causing a poor quality of life. This study was carried out to determine the frequency of RLN palsy with and without identification of nerves during thyroid surgery.

METHODOLOGY

This randomized controlled trial was carried out at Department of Surgery, Military Hospital, Rawalpindi, from August 2008 to April 2010. All patients undergoing indirect laryngoscopy with normal vocal cords were included in the study. Patients with carcinoma and re-do

¹ Department of Surgery /Anaesthesia², Military Hospital, Rawalpindi.

³ Department of Anaesthesia, Armed Forces Institute of Cardiology (AFIC), Rawalpindi.

⁴ Department of ENT, Combined Military Hospital (CMH), Rawalpindi.

Correspondence: Dr. Maqbool Ahmed, House 62, Street 8, Valley Road, Rawalpindi.

E-mail: maqbool957@hotmail.com

Received November 30, 2010; accepted January 30, 2013.

surgery having normal vocal cord were also included in the study. Patients with hoarseness of voice, abnormal vocal cord movements and with solitary nodule in the isthmus were excluded from the study.

A total of 100 patients fulfilling the inclusion criteria were included in the study and randomly divided in the two groups of 50 each using random numbers (Table I). In group-A (n = 50) nerve(s) were routinely identified and in group-B (n = 50) nerve(s) were not routinely identified.

All patients included in the study were informed about the risk of RLN palsy and whether or not their nerves were to be exposed during surgery. All cases were operated under the general anaesthesia by the consultants having variable experiences of thyroid surgery. In group-A patients, recurrent laryngeal nerve was identified across the inferior thyroid artery and traced proximally within thyroid vicinity and distally upto its entry into larynx. Any nerve injury during dissection was recorded. In group-B, the operation was completed without identifying the recurrent laryngeal nerves. Immediate postoperative direct laryngoscopy was performed by a surgeon with the help of an anaesthesiologist for the assessment of vocal cords. Patients with hoarseness of voice underwent indirect laryngoscopy by the ENT surgeon on 4th/5th post-operative day and any nerve palsy was recorded. Patients with nerve palsy were followed up by an ENT surgeon at the end of the 1st, 3rd and 6th month. Any clinical improvement in the voice was also recorded. The palsy was considered permanent if it persisted beyond 6 months.

Data was analyzed through Statistical Package for Social Sciences (SPSS) version 15. Descriptive statistics were used to describe the data i.e. mean and standard deviation for quantitative variables like age while frequency and percentages for qualitative variables like gender, nature of surgery and recurrent laryngeal nerve palsies. Independent sample t-test was used to compare quantitative variables and chi-square test was used to compare qualitative variables between the groups. P-value < 0.05 was considered as significant.

RESULTS

One hundred patients were included in the study and randomly divided into two groups of 50 each. Average age in group-A was 37.24 ± 7.88 years, while in group-B it was 40 ± 7.10 years. There were 43 (86%) females and 7 (14%) males in group-A and 45 (90%) females and 5 (10%) males in group-B. Nature of the surgery performed is given in Table I. Both the groups were comparable with respect to age ($p = 0.072$), gender ($p = 0.538$) and nature of surgery (Table I).

Recurrent laryngeal nerve palsies occurred in 2 (4%) patients in group-A while in group-B it occurred in 8

(16%) patients. Frequency of recurrent laryngeal nerve palsies was significantly lower in group-A as compared to group-B ($p = 0.046$).

In group-A, out of 2, temporary unilateral recurrent laryngeal nerve palsies occurred resulting in hoarseness of voice. In one case, the nerve was accidentally divided during dissection which was repaired. There was hoarseness of voice postoperatively and direct and indirect laryngoscopy revealed immobile cord on this side. The voice and cord movements returned to normal in 6 months. In other case, there was slight hoarseness of voice and indirect laryngoscopy revealed sluggish movements of cord on this side. The voice improved in 6 weeks.

In group-B, out of 8 injuries, 2 cases were of bilateral recurrent nerve injuries required immediate tracheostomy. In one case, tracheostomy was removed after 6 months with persistent hoarseness of voice but no respiratory difficulty during routine activities while tracheostomy was permanent in the other case. In 6 cases of unilateral nerve injuries, hoarseness of voice occurred but improved in 4 cases during period varying from 1 to 4 months while in 2 cases, it persisted even after 6 months. Comparison of RLN injuries in both groups is shown in Figure 1.

Table I: Description of nature of surgery in both the groups.

Nature of surgery	Group-A	Group-B (n = 50)	p-value (n = 50)
Total thyroidectomy for carcinoma	2 (4%)	2 (4%)	1.000
Completion thyroidectomy for carcinoma	2 (4%)	2 (4%)	1.000
Total lobectomy for recurrent papillary carcinoma	1 (2%)	0 (0%)	0.315
Bilateral near total thyroidectomy for toxic goiter	2 (4%)	2 (4%)	1.000
Bilateral subtotal thyroidectomy for MNG	20 (40%)	23 (46%)	0.544
Total lobectomy on one side and sub-total on other side for MNG	5 (10%)	3 (6%)	0.461
Lobectomy and isthmectomy for STN	16 (32%)	16 (32%)	1.000
Bilateral sub-total thyroidectomy for recurrent MNG	2 (4%)	2 (4%)	1.000

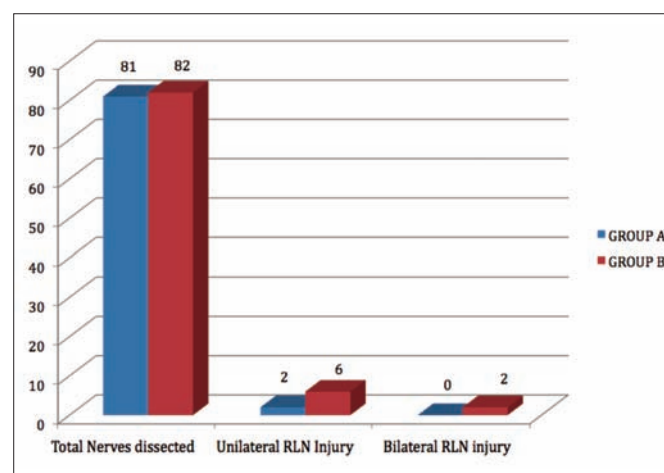


Figure 1: Comparison of RLN injuries .

DISCUSSION

The incidence of recurrent laryngeal nerves injuries varies widely, 0-14%, depending upon the experience of surgeon.⁴⁻⁶ This small study shows 20% incidence of recurrent laryngeal nerve injury, 4% in group-A where nerves were identified and 16% in group-B where the nerve was not identified. The other local studies report 3.22%,⁷ 4.7%⁸ and 13.5%⁹ chances of recurrent laryngeal nerve injury during thyroid surgery.

Injury to recurrent laryngeal nerve(s) can occur anywhere along its course in the vicinity of thyroid gland. It is usually accidentally ligated and divided in an attempt to control excessive bleeding in RLN vicinity or it may excessively stretch during surgery for large thyroid gland.¹⁰ The course of the nerve may be abnormal as result of previous surgery or nerve may have been entrapped because of malignant process resulting in increased chances of injury. Sometimes, a posteriorly lying large nodule stretches the nerve making it more vulnerable to injury. Moreover, total thyroidectomy, near total thyroidectomy and revision thyroidectomy has high chances of nerve injury.¹¹⁻¹³

The relationship of RLN with inferior thyroid artery is very variable and the surgeon must have the knowledge of these variations in order to avoid this serious injury.^{14,15} As it approaches the thyroid, it usually passes obliquely upward (more obliquely on the right) towards thyroid, passes mostly behind or between the branches of inferior thyroid artery and becomes closer to thyroid gland before entering into cricothyroid membrane. Here, the nerve is surrounded by multiple small veins in majority of cases and is most vulnerable to injury. Sometimes, it passes in front of branches of inferior thyroid artery. Occasionally, it passes in front or behind the trunk of inferior thyroid artery. Sometimes, the nerve runs parallel to inferior thyroid artery. In many cases, it divides into two branches before entering into cricothyroid membrane. Sometimes these branches are given off earlier as the nerve approaches the thyroid gland. The inferior thyroid artery is absent in few cases, mostly on the right side. In 0.5% of cases, the right nerve is non-recurrent and on rare occasions a recurrent and a non-recurrent nerve may be present on the right side.¹⁶ The severe morbidity associated with damage to these nerves can be easily avoided by identification of these nerves during operation.

The first surgeon who has advocated routine exposure of the nerve was August Bier followed by Lahey of Boston in 1938.¹⁷ Several studies demonstrate that identification of the nerve reduces the risk of permanent RLN palsy from 5% to less than 1%.^{18,19} Non-identification may lead to damage to the nerve without surgeon's knowledge. It will be recognized only during extubation or later on when the patient is symptomatic.

Majority of the injuries are transient and voice usually improves with the passage of time. Chiang *et al.* observed that it may take a period of 3 days to 4 months to recover from recurrent laryngeal nerve injury in majority of the patients.²⁰ If the surgeon has identified the nerve during operation and still there is hoarseness of voice, he can always assure the patient with confidence that voice will return to normal. But if he has not identified the nerve, he cannot be sure of this recovery.

In recent years, many surgeons have started using electrophysiological neural monitoring devices during surgery to further diminish the incidence of recurrent laryngeal nerve injury.^{21,22} Several devices have been utilized; all of them have some means of detecting vocal cord movements when the recurrent laryngeal nerve is stimulated.

CONCLUSION

Routine exposure of RLN(s) during thyroid surgery can minimize/avoid its injury. The nerve(s) course needs to be completely exposed in the thyroid vicinity as partial exposure can still lead to nerve injury because of its variable course.

REFERENCES

- Watkinson JC. Tumours of the thyroid gland. In: Jones AS, Phillips DE, Hilgers FJ, editors. Diseases of the head and neck, nose and throat. London: Arnold 1998; p 347-71.
- Fang JG, Ma HZ, Zhang ZB, Huang ZG, Chen XH, Zhou WG, *et al.* Total thyroidectomy: indications and complications. *Zhonghua Er Bi Yan Hou Tou Jing Wai Ke Za Zhi* 2010; **45**:904-7.
- Bliss RD, Gauger PG, Delbridge LW. Surgeon's approach to the thyroid gland: surgical anatomy and the importance of technique. *World J Surg* 2000; **24**: 891-7.
- Myssiork D. Recurrent laryngeal nerve paralysis: anatomy and etiology. *Otolaryngol Clin N Am* 2004; **37**:25-44.
- Mchenery CR. Patient's volume and complications in thyroid surgery. *Br J Surg* 2002; **89**:821-3.
- Tresallet C, Chigot JP, Mereganx F. How to prevent recurrent laryngeal nerve palsy during thyroid surgery. *Ann Chir* 2006; **131**:149-53.
- Choudhary IA, Samiullah, Masood R, Majrooh MA, Mallahi AA. Recurrent laryngeal nerve injury: an experience with 310 thyroidectomies. *J Ayub Medical Coll Abbottabad* 2007; **19**:26-8.
- Arif M Ahmed I. Recurrent laryngeal nerve palsy during thyroidectomies. *J Surg Pak* 2001; **6**:12-5.
- Shah SS, Khan A. Assessment of total thyroidectomy. *J Surg Pak* 2005; **10**:24-6.
- Randolph GW, Shin JJ, Grillo HC, Mathisen D, Katlic MR, Kamani D, *et al.* The surgical management of goiter: Part II. Surgical treatment and results. *Laryngoscope* 2011; **121**:68-76.
- Al-Fakhri N, Schwartz A, Rwnkel N, Buhr HJ. [Rate of complications with systemic exposure of the recurrent laryngeal nerve and parathyroid gland operation for benign thyroid disease]. *Zentralbl Chir* 1998; **123**:21-4. German.

12. Kebebew E. Near total thyroidectomy could be the best treatment for thyroid disease in endemic region. Invited critique. *Arch Surg* 2004; **139**:447.
13. Montagne S, Brunaud L, Ayav A. Recurrent nerve preservation during total thyroidectomy. *Ann Chir* 2002; **127**:449-55.
14. Yalcixin B. Anatomic configuration of recurrent laryngeal nerve and inferior thyroid artery. *Surgery* 2006; **139**:181-7.
15. JShao T, Yang W, Zhang T, Wang Y, Jin X, Li Q, *et al.* A newly identified variation at the entry of the recurrent laryngeal nerve into the larynx. *Invest Surg* 2010; **23**:314-20.
16. Defechereux T, Albert V, Alexandre J, Bonnet P, Hamoir E, Meurisse M. The inferior non-recurrent laryngeal nerve: a major surgical risk during thyroidectomy. *Acta Chirurgica Belgica* 2000; **100**:62-7.
17. Lahey FH. Routine dissection and demonstration of the recurrent laryngeal nerve in sub-total thyroidectomy. *Surg Gynecol Obstet* 1958; **66**:775-7.
18. Jatzko GR, Lisborg PH, Müller MG, Wette VM. Recurrent nerve palsy after thyroid operations: principal nerve identification and a literature review. *Surgery* 1994; **115**:139-44.
19. Wagner HE, Seiler C. Recurrent laryngeal nerve palsy after thyroid gland surgery. *Br J Surg* 1994; **81**:226-8.
20. Chiang FY, Lee KW, Huang YF, wang LF, Kuo WR. Risk of vocal cord palsy after thyroidectomy with identification of recurrent laryngeal nerve. *Kaohsiung J Med Sci* 2004; **20**:431-6.
21. Randolph GW, Dralle H. International Intraoperative Monitoring Study Group, Abdullah H, Barczynski M, Bellantone R, Brauckhoff M, *et al.* Electrophysiologic recurrent laryngeal nerve monitoring during thyroid and parathyroid surgery: international standards guideline statement. *Laryngoscope* 2011; **121**:S1-16.
22. Frattini F, Mangano A, Boni L, Rausei S, Biondi A, Dionigi G. Intraoperative neuromonitoring for thyroid malignancy surgery: technical notes and results from a retrospective series. *Updates Surg* 2010; **62**:183-7.

