

# A Case Report of Mucormycosis with Palatal Ulcer: A Rare Clinical Dilemma

Nikita Rajendrakumar Patel<sup>1</sup> and Pranjal Anil Patel<sup>2</sup>

## ABSTRACT

Mucormycosis represents a group of life-threatening infections caused by fungi of the order mucorales of subphylum mucormycotina (formerly known as the class zygomycetes). It is highly invasive and progressive disease resulting in higher rates of morbidity and mortality. Newer therapies have declined the rates of mortality. Early initiation of therapy often before confirmation of the diagnosis is necessary to optimize outcomes. Here, we report a case of mucormycosis with palatal ulcer in a 63-year male patient, which is a rare anatomic site for the occurrence of mucormycosis or is a rare clinical presentation. The patient was successfully treated with surgical debridement and amphotericin B.

**Key Words:** Mucormycosis. Palate. Ulcer.

## INTRODUCTION

Mucormycosis is an emerging angioinvasive infection caused by the ubiquitous filamentous fungi of the mucorales order of the class of zygomycetes.<sup>1</sup> Mucormycosis is an invasive fungal infection that was first described by Paulltauf A in 1885.<sup>2</sup> It is the third most common invasive mycosis in order of importance after candidiasis and aspergillosis.<sup>1</sup> During past two decades, it has emerged as an important fungal infection with high mortality rates. The clinical hallmark of invasive mucormycosis is tissue necrosis resulting from angioinvasion and subsequent thrombosis.<sup>1</sup> On the basis of the clinical presentation and particular site of involvement, six manifestations of the disease can be described: rhinocerebral, pulmonary, cutaneous, gastrointestinal, disseminated, and localised infections.<sup>3</sup> In case of mucormycosis, palate is the least common site; and ulceration with palatal perforation is late occurrence. Thus, it challenges further the outcome of treatment and causes disability of the patient. Therefore, the aim of this article is to report such a rare case of mucormycosis with palatal ulceration and add it to the literature.

## CASE REPORT

A 63-year male patient reported with the chief complaint of ulcer on the palate, and progressively increasing headache with pain in right side of the face for 20 days.

Patient gave a history of tobacco chewing since 12 years; and also had a history of diabetes, for which, he was on medication but there was no regularity of medication. Oral examination revealed edentulous upper and lower arches with palatal ulcer on right side which was approximately 3x3 cm in dimension. The base of the ulcer was soft and black in colour (Figure 1).

Mucous discharge and slough was also noted. Borders of ulcer appeared to be irregular. Based on history and clinical findings, a provisional diagnosis was made of malignancy of palate. Investigations such as CT scan, culture sensitivity test, cytopathology and histopathological examination were advised. CT scan revealed bilateral sinonasal polyposis and bone erosions involving hard palate and maxilla (Figures 2 and 3).

Cytopathological examination showed hemorrhagic and necrotic material and a few broad fungal hyphae. KOH mount revealed the presence of few broad fungal hyphae. Pus culture was also done which grew methicillin-resistant *staphylococcus aureus* (MRSA).

Biopsy was performed and tissue sample was taken. Histopathological examination showed branched, non-septate, broad, fungal hyphae, necrotic tissue, and haemorrhagic material (Figures 4a and 4b).

After the diagnosis of mucormycosis was made, further management was done by amphotericin B with monitoring of serum creatinine and serum potassium level. Amoxicillin with clavulanic acid and linezolid were also given for superadded MRSA infection and insulin for glycemic control. Patient was further managed with endoscopic surgical debridement. Patient showed clinical improvement with relief from headache, facial tenderness, slowly healing ulcer and stable renal functions.

## DISCUSSION

Mucormycosis is an infection that is caused by several species belonging to the order mucorales.<sup>4</sup> The most

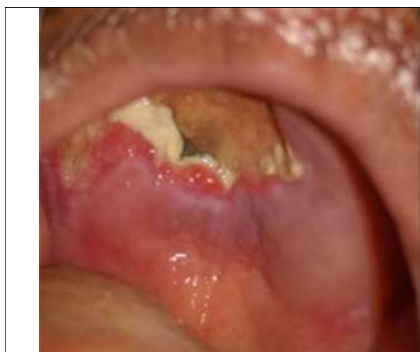<sup>1</sup> Department of Oral Pathology, SMT Institute of Dental Sciences and Research, Nashik, India.

<sup>2</sup> Department of General Medicine, Suyash Multispeciality Hospital, Nashik, India.

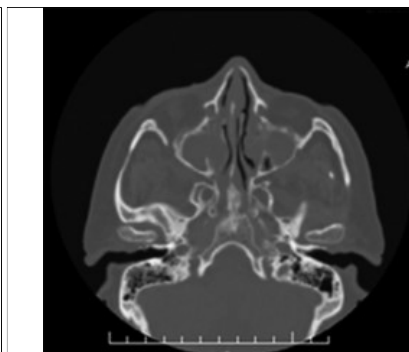
Correspondence: Dr. Nikita Rajendrakumar Patel,  
Senior Lecturer, Department of Oral Pathology, SMT Institute  
of Dental Sciences and Research, Nashik, India.

E-mail: patelnikitar.15@gmail.com

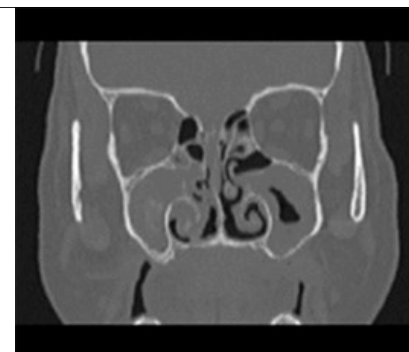
Received: August 30, 2017; Accepted: December 04, 2017.



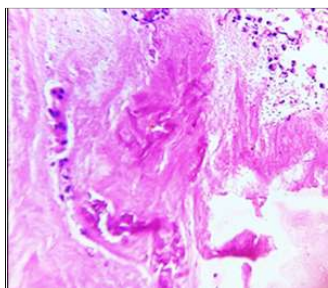
**Figure 1:** Palatal ulcer with presence of slough and black base.



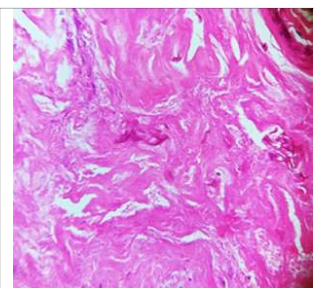
**Figure 2:** Bilateral nasal polyposis with bony erosions.



**Figure 3:** Bony erosions involving the hard palate.



**Figure 4a:** Broad, non-septate, fungal hyphae (H and E staining, x 10).



**Figure 4b:** Broad, non-septate, fungal hyphae (H and E staining, x 10).

common species causing mucormycosis are rhizopus.<sup>5</sup> The major predisposing factors responsible for mucormycosis are acute diabetes mellitus, metabolic acidosis, debilitating diseases such as leukaemia or lymphoma, and immunosuppression.<sup>6</sup> Our patient also had the history of uncontrolled diabetes and had poor compliance of medication. The infection in some cases is rapidly progressive and results in death, unless underlying risk factors (i.e. metabolic acidosis) are corrected and treatment with antifungal agents and surgical excision is instituted.<sup>1</sup> Mucorales species are vasotropic; and depending upon its anatomic site, the mucormycosis spectrum ranges from cutaneous, rhinocerebral, sinopulmonary to disseminated and frequently fatal infections, especially in immunocompromised hosts.<sup>7,8</sup> Rhinocerebral mucormycosis represents half of all cases of zygomycosis and is mostly seen in cases of uncontrolled diabetes. The most common oral sign of mucormycosis is ulceration of palate, which is rapidly progressing and results in necrosis due to invasion of a palatal vessel. Involved tissues become red, then black as tissue undergo necrosis and vessels get thrombosed.<sup>9</sup> Extension from the sinuses into the mouth causes painful, black necrotic ulceration in the hard palate.<sup>10</sup> In this case, patient presented with palatal ulceration with mucous discharge, base of the ulcer appeared black and tissue necrosis was seen on right side of hard palate. Fever and facial tenderness were also present.<sup>9</sup> Mucormycosis can be diagnosed easily by histological examination. Tissue sections involved show viable amounts of necrosis,

which may be related to infarction caused by thrombi.<sup>11</sup> Mucormycosis shows large, branching, non-septate, fungal hyphae at the periphery. A neutrophilic infiltrate usually predominates in the viable tissue.<sup>12</sup> Similar findings were seen in this case. Successful treatment of mucormycosis involves four major approaches. These are rapid correction of the underlying host conditions, (such as diabetic ketoacidosis,) antifungal therapy, surgical debridement of devitalised tissue and the use of adjunctive therapies, such as hyperbaric oxygen.<sup>5</sup> Recently, intravenous liposomal amphotericin, intravenous lipid complex, and hyperbaric oxygen therapy have been used.<sup>9</sup> The principle behind hyperbaric oxygen therapy is that it reduces tissue hypoxia and acidosis that occur with vascular invasion of mucormycosis.<sup>5</sup> The prognosis of the disease depends on overall earlier diagnosis and earlier management, which results in better outcome of the disease.

We suggest that mucormycosis associated with palatal ulcer should be considered in the differential diagnosis of hard palate ulcer as it is uncommon clinical diagnosis. Mucormycosis is a rare emerging fungal infection with a high rate of mortality. It is very important to control and prevent opportunistic fungal infections in patients suffering from debilitating diseases. Rapid diagnosis with prompt surgical debridement and antifungal therapy is important for the better outcome of the disease.

## REFERENCES

- Petrikos G, Skiada A, Lortholary O, Roilides E, Walsh TJ, Kontoyiannis DP. Epidemiology and clinical manifestations of mucormycosis. *Clin Infect Dis* 2012; **54**:S23-34.
- Jain A, Jain R, Banyameen IM, Shetty T. Mucormycosis of the hard palate: a rare case report. *Tanta Med J* 2014, **42**:112-4.
- Spellberg B, Edwards JJr, Ibrahim A. Novel perspectives on mucormycosis: pathophysiology, presentation and management. *Clin Microbiol Rev* 2005; **111**:509-47.
- Smith AG, Busstamante CI, Gilmore GD. Zygomycosis (absidiomycosis) in an AIDS patient. *Mycopathologia* 1989; **105**:7-10.
- Bist SS, Varshney S, Bisht M, Gupta N, Bhatia R. Isolated palate ulcer due to mucormycosis. *Indian J. otolaryngol. Head Neck Surg* 2008; **60**:79-82.

6. Arora DR, Brijbala A. In chapter: Medical Mycology 5th ed. Textbook of microbiology. CBS Publisher 2016; p.590-1.
7. Gonzalez CE, Rinaldi MG, Sugar AM. Mucormycosis. *Infect Dis Clin North Am* 2002; **16**:895-914.
8. Rogers TR. Treatment of mucormycosis: current and new options. *J Antimicrob Chemother* 2008; **61**(Suppl 1):35-9.
9. Jayachandran S, Krithia C. Mucormycosis presenting as palatal ulceration. *Indian J Dent Res* 2006; **17**:139-42.
10. Ribes JA, Vanover CL, Baker DJ, Zygomycetes in human diseases. *Clin Microbiol Rev* 2000; **13**:236-301.
11. Sivapathasundharam B. In chapter: Mycotic Infections. 8th ed. Shafer's textbook of oral pathology. Elsevier 2016; p.348-9.
12. Neville BW, Damn DD, Allen CM. In chapter: Fungal and protozoal diseases 3rd ed. Oral and maxillofacial pathology. Elsevier 2009; p.232-3.

