

# Ghrelin improves rat sperm kinematic parameters during abdominal position of the testis

Kheradmand, A.\*

Department of Clinical Sciences, School of Veterinary Medicine, Lorestan University, Khorram Abad, Iran

## Key words:

cryptorchidism, ghrelin, rat, sperm quality

## Correspondence

Kheradmand, A.\*

Department of Clinical Sciences,  
School of Veterinary Medicine,  
Lorestan University, Khorram Abad,  
Iran

Tel: +98(661) 6200109

Fax: +98(661) 6200109

Email: arashkheradmand@yahoo.com

Received: 15 January 2014

Accepted: 9 April 2014

## Abstract:

**BACKGROUND:** Disruption of testicular function and arrest of spermatogenesis are the consequence of cryptorchidism in response to elevated temperature. **OBJECTIVES:** This investigation was set to clarify the possible ghrelin efficacy in altering some sperm quality parameters upon experimentally-induced cryptorchidism. **METHODS:** Thirty male adult rats were scheduled for the study and were divided into three groups: group 1 was served as control-saline (CS), group 2 was designed as cryptorchidism-saline (CrS), and group 3 was defined as cryptorchidism-ghrelin (CrG). After surgically inducing cryptorchidism in groups 2 and 3, the researchers gave 10 nmol of ghrelin to CrG rats for 7 consecutive days. Five animals in each group were equally killed on days 3 and 7 after operation and their testes were taken for sperm evaluation. **RESULTS:** Testicular weight, sperm forward progressive motility (FPM), functional membrane integrity (assessed by HOS-test), and sperm concentration displayed slight changes after heating on day 3. However, abdominal position of the testes for 7 days caused a significant reduction in the percentages of HOS-positive cells ( $p < 0.0001$ ), FPM ( $p < 0.0001$ ), and sperm concentration ( $p < 0.01$ ). Although a 30% decrease occurred in the testicular weight at this point, however, this reduction was not statistically significant. Interestingly, HOS-test and FPM percentages were significantly higher in the ghrelin-exposed animals compared to the CrS group on day 7 ( $p < 0.05$ ). However, ghrelin treatment had not considerable influence on sperm parameters by day 3. Moreover, sperm concentration and testicular weight did not exhibit any changes either on day 3 or at day 7 upon ghrelin injection ( $p > 0.05$ ). **CONCLUSIONS:** Indeed, this function of ghrelin could be attributed to its antioxidant properties and it may be implicated as a potential agent in attenuation of impaired spermatogenesis after cryptorchidism.

## Introduction

It has been established that in mammals, lower scrotal temperature is required for normal spermatogenesis (Shikone et al., 1994). Failure in testicular descending into the scrotum or cryptorchidism induced by surgery in rats results in disruption of spermatogenesis (Jegou et al., 1983). The spermatogenesis disorder and subsequent male infertility is

due to the germ cell loss in response to abdominal elevated temperature (Liu et al., 2012). It has been well shown that an increased level of reactive oxygen species (ROS) and lipid peroxidation, as sign of oxidative stress, are associated with cryptorchid testes which cause impaired spermatogenesis (Peltola et al., 1995; Kumagai et al., 2002). Changes in the lipids containing polyunsaturated fatty acids have also been indicated (Furland et al., 2007).

Therefore, it seems that antioxidant therapy may attenuate the adverse effects of ROS on the spermatogenesis and inhibit the changes in spermatozoa membrane lipids during cryptorchidism.

It has been recently proposed that ghrelin is an endogenous antioxidant and functions as a free radical scavenger (Dong and Kaunitz, 2006). The antioxidative properties of ghrelin via increasing the antioxidant enzymes activities and reducing lipid peroxidation have been newly reported in our laboratory in the normal rat testis (Kheradmand et al., 2009a,b) and ovary (Kheradmand et al., 2010), as well as in other tissues such as preadipocyte cell culture (Zwirska-Korczała et al., 2007) and gastric injuries (Iseri et al., 2005; El Eter et al., 2007). The ghrelin gene is expressed in stomach, small intestine, brain, pituitary, salivary gland, adrenal, ovary, and testis (Ghelardoni et al., 2006). Within the testis, expression of ghrelin has been demonstrated in mature Leydig cells of rats and humans. In addition, expression of the functional ghrelin receptor, the GHS-R type 1a, has been shown in Sertoli and Leydig cells (Tena-Sempere, 2005; Barreiro and Tena-Sempere, 2004). The expression of GHS-R 1a in the seminiferous tubules strongly suggests that the seminiferous epithelium might be a target for ghrelin action and directly regulates seminiferous tubules function (Barreiro and Tena-Sempere, 2004).

Thus, with regard to these literatures, this study attempted to examine the possible ghrelin protective effects on rat sperm quality and membrane integrity following experimentally induced cryptorchidism.

## Materials and Methods

**Animals:** Thirty male Wistar rats weighing 200 to 220 gr were used for the experiment. The animals were maintained under constant conditions of light (12 h of light, from 07:00 h) in an animal room in groups of five rats per cage and controlled temperature (21-24°C) with free access to pelleted food and tap water. Rat lyophilised acylated ghrelin (n-octanoylated research grade) were purchased from Tocris Cookson Ltd. (Bristol, UK).

**Surgical technique:** The animals were randomly divided into three equal groups (each containing 10 rats): group 1 was served as sham-operated or control-saline (CS), group 2 was defined as cryptor-

chidism-saline (CrS), and group 3 was assumed as cryptorchidism-ghrelin (CrG) animals. Surgical procedure for induction of bilateral cryptorchidism was performed according to the method of inguinoscrotal approach as previously described by Dundar et al. (2001). General anesthesia was achieved intraperitoneally by a combination of 70 mg kg<sup>-1</sup> of ketamin and 5 mg kg<sup>-1</sup> of xylazine hydrochloride. After anesthesia, the scrotal area was shaved and prepared by povidone iodine solution. In groups 2 and 3, inguinoscrotal region was incised and gubernaculum was separated where it protruded from the abdominal wall, and then the external inguinal ring was revealed. After pushing the gubernaculum into the abdominal cavity, the external inguinal ring and inguinoscrotal wall was closed by 2.0 simple silk suture. During the sham operation, both testes were brought through the incision and then replaced after a few manipulations. Immediately after surgery, CrG rats were given ghrelin subcutaneously (10 nmol/100 µL saline) for 7 consecutive days. Five rats from each group were killed upon diethyl ether anesthesia by decapitation on days 3 and 7 after surgery for sperm evaluation parameters.

**Sperm collection and evaluation:** Immediately after rats were killed and the weight of each testicle was measured, the right epididymis of three groups were removed and trimmed of fat. Rat spermatozoa were obtained using Cancel et al.'s (2000) method. Briefly, 5 mm of right cauda epididymis was minced in 2-ml of physiological saline and incubated at 37°C for 30 min to allow dispersion of spermatozoa. The obtained spermatozoa from all groups were assessed for forward progressive movement, plasma membrane integrity, and sperm concentration.

The FPM percentage (of the motile spermatozoa showing progressive movement) was assessed according to the method as previously described by Sonmez et al. (2005). The fluid obtained from cauda epididymis was diluted to 2 mL of PBS and an aliquot of this suspension was placed on the microscope slide covered with a coverslip and examined visually under a light microscope at the magnification of 400. Motility estimations were performed from four different fields in each sample and the mean of the four estimations was used as the final motility score. Samples for motility evaluation were kept at 37°C.

To evaluate the membrane integrity, hypoosmotic

swelling (HOS) test was applied. Assessment of functional integrity of sperm membrane was determined by HOS-water test according to the method as described previously by Sliwa and Macura (2005). In short, 10  $\mu$ L of sperm was added into 0.4 mL of distilled water and incubated for 5 minutes at 37°C. The swelling reaction was measured by counting of spermatozoa with curled tail using a light microscope at magnification of 400. All of the examinations above were performed by the same person, counting at least 100 sperms.

The concentration of spermatozoa was determined after adding 50  $\mu$ L of sperm into the 1 mL of formalin-saline to achieve the dilution rate of 1:20. Approximately, 10  $\mu$ L of the diluted sperm suspension was transferred to each counting chamber of the haemocytometer and the total number of spermatozoa per mL was counted with the help of light microscope.

**Statistical analysis:** Results were analyzed using the SPSS/PC program. All data were tested for normality and thereafter by Levene static test for homogeneity of variance. When the variance was homogenous, testicular weight, FPM, HOS-positive percentage, and sperm concentration among the CS, CrS, and CrG rats at different days were separately analyzed using one-way ANOVA and Tukey test as post hoc, in order to determine the difference among groups (Petrie and Watson, 1999). Data are presented as mean  $\pm$  SEM.

## Results

**Testicular weight:** Abdominal position of the testes was associated with not significant decrease in testicular weight particularly on day 7. However, the changes were negligible after 3 days of exposure to heat. As indicated in figure 1, ghrelin treatment was not able to enhance testicular weight to its normal value up to day 7 ( $p > 0.05$ ).

**Assessment of sperm motility:** The results of the FPM analysis are depicted in Figure 2. Testicular hyperthermia resulted in a drastic decrease in the percentages of FPM in both CrS and CrG animals on day 7 ( $p < 0.0001$ ). Notably, ghrelin administration significantly promoted FPM rate compared to the CrS rats ( $19.80 \pm 1.85\%$  versus  $4.40 \pm 2.11\%$ ) on day 7 ( $p < 0.01$ ). However, it was still lower than that of the

control group at this point ( $p < 0.001$ ).

**Plasma membrane integrity:** Exposure to abdominal heat for three days did not affect the mean values of HOS-reactive spermatozoa among groups. In contrast, examining the data revealed that the spermatozoa with functionally intact membrane were reduced by day 7 after surgery in both CrS and CrG animals ( $p < 0.01$ , Figure 3). Ghrelin exposure could enhance the percentage of HOS-positive cells compared to the CrS group at day 7 ( $38.80 \pm 3.78\%$  versus  $22.40 \pm 4.38\%$ ,  $p < 0.05$ ).

**Sperm concentration:** Abdominal testicular temperature caused a marked reduction in the number of spermatozoa on day 7 ( $p < 0.01$ ). However, the comparison of the data on day 3 did not exhibit significant differences among groups. In addition, ghrelin failed to alter the sperm number compared to the CrS rats on day 7 ( $p > 0.05$ , Figure 4.).

## Discussion

The results of the present study are probably the first which clearly demonstrated the ghrelin ability in promotion of main sperm quality parameters, progressive motility, and functional membrane integrity following experimentally-induced cryptorchidism in the rat testis. However, it failed to change the sperm concentration and testicular weight upon treatment.

The expression of functional ghrelin receptor in the seminiferous tubules strongly suggests that the seminiferous epithelium might be a target for ghrelin action and might directly regulate seminiferous tubules functions (Barreiro and Tena-Sempere, 2004). In human, a positive correlation between the percentage of swollen sperm and that of motile sperm was seen (Chan et al., 1985). Likewise, the high correlation ( $r = 0.90$ ) between the percentage of sperm in semen sample that were capable of swelling and the percentage of zona-free hamster oocytes that were penetrated by sperms from the same semen samples were found (Jeyendran et al., 1984). This may be the reason of why the sperm motility rate is greater in the treated animals when the HOS percentage was high. Because in the current work, the increase in the HOS-positive cells in the ghrelin-exposed animals was associated with the simultaneous and significant improvement in the FPM rate by day 7.

The sperm plasma membrane contains a high

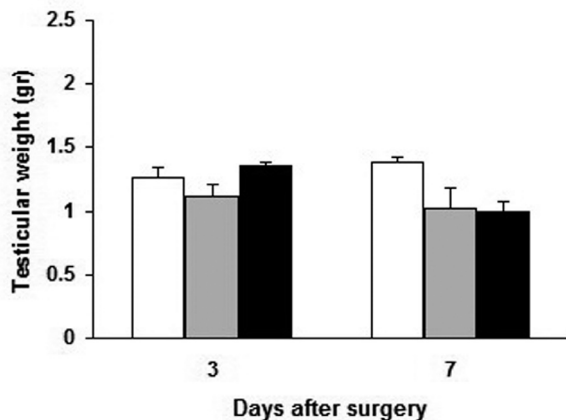


Figure 1. Mean  $\pm$  SEM of testicular weight on 3<sup>th</sup> and 7<sup>th</sup> days after induction of cryptorchidism in three experimental groups. The data did not represent significant differences among groups.  
 □ Control-saline    ■ Cryptorchidism-saline  
 ■ Cryptorchidism-ghrelin

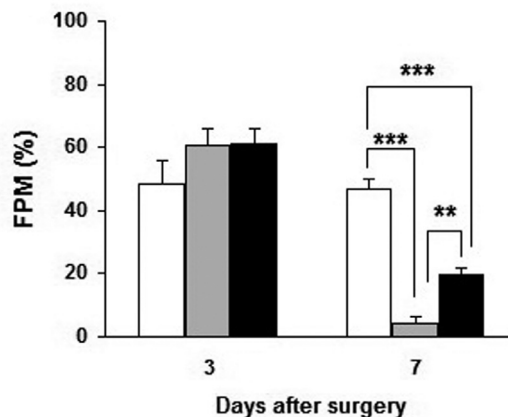


Figure 2. Mean  $\pm$  SEM of FPM percentages on 3<sup>th</sup> and 7<sup>th</sup> days after induction of cryptorchidism in three experimental groups. All means marked with \*(p<0.05), \*\*(p<0.01) and \*\*\*(p<0.001) are significantly different from each other.  
 □ Control-saline    ■ Cryptorchidism-saline  
 ■ Cryptorchidism-ghrelin

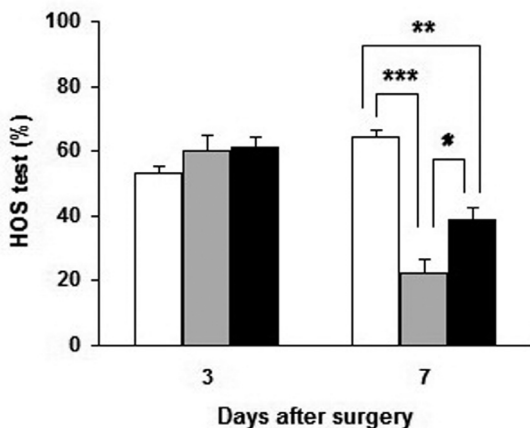


Figure 3. Mean  $\pm$  SEM of HOS test percentages on 3<sup>th</sup> and 7<sup>th</sup> days after induction of cryptorchidism in three experimental groups. All means marked with \*(p<0.05), \*\*(p<0.01) and \*\*\*(p<0.001) are significantly different from each other.  
 □ Control-saline    ■ Cryptorchidism-saline  
 ■ Cryptorchidism-ghrelin

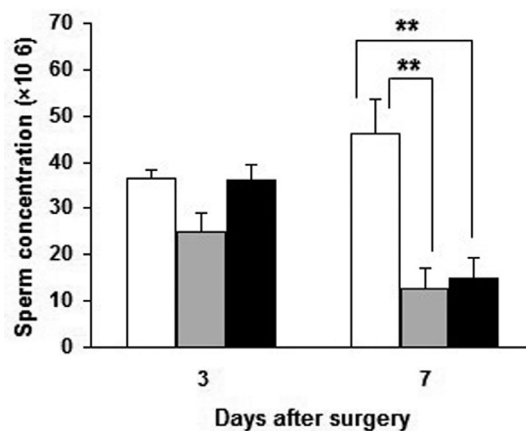


Figure 4. Mean  $\pm$  SEM of sperm concentration on 3<sup>th</sup> and 7<sup>th</sup> days after induction of cryptorchidism in three experimental groups. All means marked with \*(p<0.05), \*\*(p<0.01) and \*\*\*(p<0.001) are significantly different from each other.  
 □ Control-saline    ■ Cryptorchidism-saline  
 ■ Cryptorchidism-ghrelin

amount of unsaturated fatty acids which can be attacked by ROS and therefore is particularly susceptible to peroxidative damages with subsequent loss of membrane integrity, impaired cell function and decreased motility of spermatozoa. This oxidative stress is one of the factors associated with decline in fertility of spermatozoa (Aitken et al., 1989; Tramer et al., 1998). Furthermore, the high level of polyunsaturated fatty acids in mammalian testes previously reported (Aitken et al., 1989; Robinson et al., 1992) suggests that the plasma membranes of most testicular cells may be greatly

susceptible to free radical attack. In this sense, it has been well documented that impaired detoxification of ROS results in the oxidative stress and increased peroxidation of cellular lipids in abdominal position of the testes (Ahotupa and Huhtaniemi, 1992; Peltola et al., 1995; Furland et al., 2007).

It is believed that ghrelin is one of the endogenous antioxidants that attenuate the oxidative stress responses (Dong and Kaunitz, 2006). Therefore, enhancement of the HOS-reactive spermatozoa following ghrelin administration is possibly due to the antioxidant properties of this hormone which

resulted in higher motility index 7 day after operation. This may be the reason for greater sperm motility in the treated animals simultaneous with increment in the HOS percentage.

In most mammalian species, the testis is kept approximately 4-5°C below body temperature. It is well established that cryptorchidism induced by surgery results in disruption of spermatogenesis (Liu et al., 2012; Barqawi et al., 2004). Cryptorchidism induces complete arrest of spermatogenesis by 2 days (Kumar et al., 2012) or 4 days (Barqawi et al., 2004) of post operation. In cryptorchid rats, spermatogenic arrest is associated with the formation of multinuclear giant cells leading to large scale apoptosis and elimination of germ cells from the seminiferous epithelium. Subsequently, many large and small giant cells populate the affected tubules (Kumar et al., 2012; Barqawi et al., 2004). It was indicated that the percentage of motile spermatozoa started to decrease not significantly 1 day after surgery; however, it decreased significantly and reached to 50% of the control group level on day 5 of post operation (Ren et al., 2006). In the present study, the percentages of FPM were unchanged among groups until day 3; however, there was a drastic reduction in the spermatozoa showing progressive movement on day 7. However, the most surprising finding in the current study was the beneficial effects of ghrelin on sperm kinematic parameter, to a point that it could significantly elevate the sperm motility in CrG animals on day 7. In fact, it seems that the improvement in the functional membrane integrity (HOS reaction) on 7 days after ghrelin administration resulted in the greater sperm motility at this point. This action of ghrelin is probably mediated through its antioxidant properties. We have demonstrated that ghrelin significantly increases antioxidant enzyme activities and reduces MDA level, as lipid peroxidation marker, in the rat normal testis (Kheradmand et al., 2009a). Likewise, very recently, we have shown that ghrelin acts as a suppressor of testicular histopathological damage following experimentally induced cryptorchidism in the rat (Kheradmand et al., 2014).

The sperm concentration was another parameter that was investigated in our study. It was shown that testicular sperm count begins to decline rapidly at day 7 after cryptorchidism induction (Barqawi et al., 2004). Abdominal temperature caused a marked drop

in the number of spermatozoa in both CrS and CrG groups on day 7. However, ghrelin was not able to enhance sperm concentration prominently. The action of ghrelin upon testicular stem cell factor (SCF) mRNA expression may have implications not only in Leydig cell proliferation, but also in the control of spermatogenesis. SCF has been pointed out as the major paracrine stimulator of germ cell development, and it also acts as a survival factor for spermatogonia, spermatocytes and spermatids in the adult rat seminiferous epithelium (Budak et al., 2006; Hakovitra et al., 1999). In this sense, intratesticular injection of ghrelin (15 µg for 2 day) in adult rats inhibited expression of the gene encoding stem cell factor (SCF), a key signal in spermatogenesis and putative regulator of Leydig cell development. Thus it was logical for ghrelin not to be able to alter sperm count remarkably. A similar result was also obtained in our earlier report in which the sperm concentration was unchanged during ghrelin therapy in the normal healthy rats (Kheradmand et al., 2009b).

In conclusion, this study indicated the ghrelin efficacy in improvement of rat sperm quality, forward progressive movement and functional membrane integrity, following exposure to abdominal temperature induced by experimental cryptorchidism. This may have potential implication that ghrelin could be used as a promising agent for spermatogenesis recovery in the heat-induced infertility.

## Acknowledgments

This study was financially supported by research project (No. 906021) of Research Vice-Chancellery of Lorestan University in common to Lorestan University of Medical Sciences, Iran.

## References

1. Ahotupa, M., Huhtaniemi, I. (1992) Impaired detoxification of reactive oxygen and consequent oxidative stress in experimentally cryptorchid rat testis. *Biol Reprod.* 46: 1114-1118.
2. Aitken, R.J., Clarkson, J.S., Fishel, S. (1989) Generation of reactive oxygen species, lipid peroxidation and human sperm function. *Biol Reprod.* 41: 183-197.
3. Barqawi, A., Tummer, H., Meacham, R. (2004)

- Effect of prolonged cryptorchidism on germ cell apoptosis and testicular sperm count. *Asian J Androl.* 6: 47-51.
4. Barreiro, M.L., Tena-Sempere, M. (2004) Ghrelin and reproduction: a novel signal linking energy status and fertility? *Mol Cell Endocrinol.* 226: 1-9.
  5. Budak, E., Fernandez-Sanchez, M., Bellver, J., Cervero, A., Simon, C., Pellicer, A. (2006) Interactions of the hormones leptin, ghrelin, adiponectin, resistin and PYY3-36 with the reproductive system. *Fertil Steril.* 85: 1563-1581.
  6. Cancel, A.M., Lobdell, D., Mendola, P., Perreault, S.D. (2000) Objective evaluation of hyperactivated motility in rat spermatozoa using computer-assisted sperm analysis. *Hum Reprod.* 15: 1322-1328.
  7. Chan, S.Y., Fox, E.J., Chan, M.M.C. (1985) The relationship between the human sperm hypoosmotic swelling test, routine semen analysis, and the human sperm zona-free hamster ovum penetration assay. *Hum Reprod.* 44: 668-672.
  8. Dong, M.H., Kaunitz, J.D. (2006) Gastroduodenal mucosal defense. *Curr Opin Gastroenterol.* 22: 599-606.
  9. Dundar, M., Kocak, I., Culhaci, N. (2001) A new experimental model for cryptorchidism: inguinoscrotal approach. *Urol Res.* 29: 178-181.
  10. El Eter, E., Al Tuwarijiri, A., Hagar, H., Arafa, M. (2007) In vitro and in vivo antioxidant activity of ghrelin: attenuation of gastric ischemic injury in the rat. *J Gastroen Hepatol.* 22: 1791-1799.
  11. Furland, N.E., Maldonado, E.N., Aresti, P.A., Avelandano, M.I. (2007) Changes in lipids containing long-and very long chain polyunsaturated fatty acids in cryptorchid rat testes. *Biol Reprod.* 77: 181-188.
  12. Ghelardoni, S., Carnicelli, V., Frascarelli, S., Ronca-Testoni, S., Zucchi, R. (2006) Ghrelin tissue distribution: comparison between gene and protein expression. *J Endocrinol Invest.* 29: 115-121.
  13. Hakovitra, H., Yan, W., Kaleva, M., Zhang, F., Vanttinen, K., Morris, P.L., Soder, M., Parvinen, M., Toppari, J. (1999) Function of stem cell factor as a survival factor of spermatogonia and localization of messenger ribonucleic acid in the rat seminiferous epithelium. *Endocrinology.* 140: 1492-1498.
  14. Jegou, B., Laws, A.O., Kretser, D.M. (1983) The effect of cryptorchidism and subsequent orchidopexy on testicular function in adult rats. *J Reprod Fertil.* 69: 137-145.
  15. Jeyendran, R.S., Van Der Ven, H.H., Perez-Pelaez, M., Crabo, B.G., Zaneveld, L.J.D. (1984) Development of an assay to assess the functional integrity of the human sperm membrane and its relationship to other semen characteristics. *J Reprod Fertil.* 70: 219-228.
  16. Kheradmand, A., Alirezaei, M., Asadian, P., Rafiei Alavi, E., Joorabi, S. (2009a) Antioxidant enzyme activity and MDA level in the rat testis following chronic administration of ghrelin. *Andrologia.* 41: 335-340.
  17. Kheradmand, A., Taati, M., Babaei, H. (2009b) The effects of chronic administration of ghrelin on rat sperm quality and membrane integrity. *Anim Biol.* 59: 159-168.
  18. Kheradmand, A., Dezfoulian, O., Alirezaei, M., Hadian, B. (2014) Ghrelin is a suppressor of testicular damage following experimentally induced cryptorchidism in the rat. *J Pediatr Surg.* 49: 593-98.
  19. Kheradmand, A., Alirezaei, M., Birjandi, M. (2010) Ghrelin promotes antioxidant enzyme activity and reduces lipid peroxidation in the rat ovary. *Regul Pept.* 162: 84-89.
  20. Kumar, V., Misro, M.M., Datta, K. (2012) Simultaneous accumulation of hyaluronan binding protein 1 (HABP1/p32/gC1qR) and apoptotic induction of germ cells in cryptorchid testis. *J Androl.* 33: 114-121.
  21. Iseri, S.O., Sener, G., Yuksel, M., Contuk, G., Cetinel, S., Gedik, N., Yegen, B.C. (2005) Ghrelin against alendronate-induced gastric damage in rats. *J Endocrinol.* 187: 399-406.
  22. Liu, F., Huang, H., Xu, Z., Qian, X.J., Qiu, W.Y. (2012) Germ cell removal after induction of cryptorchidism in adult rats. *Tissue Cell.* 44: 281-287.
  23. Peltola, V., Huhtaniemi, I., Ahotupa, M. (1995) Abdominal position of the rat testis is associated with high level of lipid peroxidation. *Biol Reprod.* 53: 1146-1150.
  24. Petrie, A., Watson, P. (1999) *Statistics for Veterinary and Animal Science.* (1<sup>st</sup> ed.) Blackwell Science, London, UK.
  25. Robinson, B.S., Johnson, D.W., Poulos, A. (1992) Novel molecular species of sphingomyelin containing 2-hydroxylated polyenoic very-long-chain fatty acids in mammalian testes and spermatozoa. *J Biol Chem.* 267: 1746-1751.

26. Shikone, T., Billig, H., Hsueh, A.J.W. (1994) Experimentally induced cryptorchidism increases apoptosis in rat testis. *Biol Reprod.* 51: 865-872.
27. Sliwa, L., Macura, B. (2005) Evaluation of cell membrane integrity of spermatozoa by hypoosmotic swelling test-water test in mice after intraperitoneal daidzein administration. *Arch Androl.* 51: 443-448.
28. Sonmez, M., Turk, G., Yuce, A. (2005) The effect of ascorbic acid supplementation on sperm quality, lipid peroxidation and testosterone levels of male Wistar rats. *Theriogenology.* 63: 2063-2072.
29. Tena-Sempere, M. (2005) Ghrelin: novel regulator of gonadal function. *J Endocrinol Invest.* 28: 26-29.
30. Tramer, F., Rocco, F., Micali, F., Sandri, G., Panfili, E. (1998) Antioxidant systems in rat epididymal spermatozoa. *Biol Reprod.* 59: 753-758.
31. Zwirska-Korczala, K., Adamczyk-Sowa, M., Sowa, P., Pilc, K., Suchanek, R., Pierzchala, K., Namyslowski, G., Misiolek, M., Sadowski, K., Kato, I., Kuwahara, A., Zabielski, R. (2007) Role of leptin, ghrelin, angiotensin II and orexins in 3T3 L1 preadipocyte cells proliferation and oxidative metabolism. *J Physiol Pharmacol.* 58: 53-64.

## تأثیر هورمون گرلین بر پارامترهای ارزیابی اسپرم متعاقب قرار گرفتن بیضه در محوطه شکمی

آرش خردمند\*

گروه علوم درمانگاهی، دانشکده دامپزشکی دانشگاه لرستان، خرم‌آباد، ایران

(دریافت مقاله: ۲۵ دی ماه ۱۳۹۲، پذیرش نهایی: ۲۰ فروردین ۱۳۹۲)

### چکیده

**زمینه مطالعه:** اختلال در عملکرد بیضه و توقف روند اسپرماتوژنز، از عواقب افزایش دمای بیضه در عارضه کریپتورکیدیسم می‌باشد. **هدف:** این مطالعه جهت تعیین احتمال قابلیت هورمون گرلین در تغییر بعضی پارامترهای کیفیت اسپرم متعاقب ایجاد کریپتورکیدیسم تجربی انجام گرفت. **روش کار:** تعداد ۳۰ موش رت نر بالغ برای این مطالعه در نظر گرفته شده و به ۳ گروه زیر تقسیم شدند: گروه ۱ تحت عنوان کنترل - سالین (CS)، گروه ۲ تحت عنوان کریپتورکیدیسم - سالین (CrS) و گروه ۳ تحت عنوان کریپتورکیدیسم - گرلین (CrG). پس از ایجاد کریپتورکیدیسم از طریق جراحی در گروه‌های ۲ و ۳، ده نانومول گرلین به مدت ۷ روز پیاپی به گروه CrG تزریق شد. سپس ۵ موش از هر گروه بطور مساوی در روزهای ۳ و ۷ پس از جراحی کشته شده و بیضه آنها جهت ارزیابی اسپرم برداشته شدند. **نتایج:** وزن بیضه، درصد حرکات پیشرونده اسپرم، سلامت غشاء اسپرم (ارزیابی شده توسط آزمون HOS) و غلظت اسپرم تغییرات اندکی را در روز ۳ نشان دادند. اما در روز ۷ پس از ایجاد کریپتورکیدیسم، کاهش معنی داری در درصد اسپرم‌های HOS مثبت ( $p < 0/0001$ )، حرکات پیشرونده ( $p < 0/0001$ ) و غلظت اسپرم ( $p < 0/01$ ) پدید آمد. علیرغم کاهش ۳۰ درصدی وزن بیضه در این روز، اما این کاهش از لحاظ آماری معنی دار نبود. نکته قابل توجه اینکه درصد HOS و حرکات پیشرونده در روز ۷ بطور معنی داری در حیواناتی که گرلین دریافت کرده بودند در مقایسه با گروه CrS بیشتر بود ( $p < 0/05$ ). اما درمان با گرلین تأثیر معنی داری بر پارامترهای اسپرم در روز ۳ نداشت. همچنین غلظت اسپرم و وزن بیضه‌ها در گروه CrG چه در روز ۳ و چه در روز ۷ تغییر چشمگیری را نشان نداد. **نتیجه‌گیری نهایی:** در حقیقت، می‌توان این عمل گرلین را به خاصیت آنتی‌اکسیدانی آن نسبت داد و نیز می‌توان از این هورمون به عنوان یک ماده مؤثره در کاهش اختلالات اسپرماتوژنز متعاقب کریپتورکیدیسم استفاده نمود.

واژه‌های کلیدی: کریپتورکیدیسم، گرلین، رت، کیفیت اسپرم

(\* نویسنده مسؤول: تلفن: ۰۹۸(۰۶۶۱)۶۲۰۱۰۹؛ نمابر: ۰۹۸(۰۶۶۱)۶۲۰۱۰۹؛ Email: arashkheradmand@yahoo.com