

The Gulf Journal of Oncology



Indexed By PubMed and Medline Database

Issue 20, January 2016
ISSN No. 2078-2101



The Official Journal of the Gulf Federation For Cancer Control

Table of Contents

Original Articles

A Retrospective Comparative Study of Concomitant Chemoradiotherapy followed by Adjuvant Temozolomide Versus Radiotherapy Alone In Newly Diagnosed Glioblastoma Multiforme – An Experience at Radium Institute, Patna Medical College and Hospital, India	06
S. Raj, P.N. Pandit, K. Kishor	
EGFR and HER–2/neu Expression in Gallbladder Carcinoma: An Institutional Experience	12
R. Hadi, M.C. Pant, N. Husain, A. Singhal, R. Khurana, G.R. Agarwal, S. Masood, N.P. Awasthi	
Potential Co–Relation Between Chronic Periodontitis And Cancer – An Emerging Concept	20
T.G. Shrihari, V. Vasudevan, V. Manjunath, D. Devaraju	
Primary Parotid Lymphoma From A Regional Cancer Center in South India	25
B.K. Govind, K.C. Lakshmaiah, D. Lokanatha, B.Suresh, C.S. Premalata, C.R. Rao, L.J. Abraham, K.N. Lokesh, L.K. Rajeev, V. Arroju, V. Sathyanarayanan	
Honey on oral mucositis: A Randomized controlled trial	30
J. L. Jayalekshmi, R. Lakshmi, A. Mukerji	
Clinical Characteristics and prognostic analysis of Triple–negative Breast Cancer: Single institute experience	38
V.V. Maka, H. Panchal, S.N. Shukla, S.S. Talati, P.M. Shah, K.M. Patel, A.S. Anand, S.A. Shah, A.A. Patel, S. Parikh	
Histopathological pattern of thyroid diseases among patients in Hadhramout–Yemen	45
F.O. Aram, A.A. Bahannan, S.S. Bafakeer	
Exploring the Clinicopathological Parameters Affecting the Outcome in Egyptian Patients with Multiple Myeloma	51
Y. A. Sallam, M.A. Samra, A. A. Gaber	
Multidetector CT (MDCT) Findings Of Primary Hepatic Lymphoma	64
A. El–Badrawy, A. M. Tawfik, W. Mahmoud, E. Abdel–Salam, M.M. Taalab, O. Farouk, Y. Zakaria, A.M. Shebl, H. Al–Haddad	
Mobile Phone Use and the Risk of Parotid Gland Tumors: A Retrospective Case–Control Study	71
K. AL–Qahtani	
Clinicopathological Spectrum Of Gall Bladder Cancer In Kashmir – An Institutional Study	79
R. Makhdoomi, N. Bashir, N. Bhat, S.Bashir, F. Mustafa, A. Aiman, A. Charak, S. Hussain, S. Shafi, S. Bhat, N. Bashir, Z. Zahir, P. Shah	

Review Article

Chronic Inflammation and Cancer: Paradigm on Tumor Progression, Metastasis and Therapeutic Intervention	86
S. Khan, M. Jain, V. Mathur, SMA Feroz	

Conference Highlights/Scientific Contributions

• News Notes	94
• Advertisements	98
• Scientific events in the GCC and the Arab World for 2016	99



Original Study

Primary Parotid Lymphoma From A Regional Cancer Center in South India

B.K. Govind¹, K.C. Lakshmaiah¹, D. Lokanatha¹, B.Suresh¹, C.S. Premalata², C.R. Rao², L.J. Abraham¹, K.N. Lokesh¹, L.K. Rajeev¹, V. Arroju¹, V. Sathyanarayanan¹

¹Department of Medical Oncology, Kidwai Memorial Institute of Oncology, Bangalore, Karnataka, India.

²Department of Pathology, Kidwai Memorial Institute of Oncology, Bangalore, India

Abstract

Primary parotid lymphoma (PPL) is an unusual entity and there is limited data in Indian population. Hence we undertook this retrospective observational study of primary parotid lymphoma at our Center in Southern India. This study includes 7 consecutive cases diagnosed as PPL by tissue biopsy/superficial/deep parotidectomy confirmed by immunohistochemistry between January 2007 and December 2012.

Results

Median age was 54 years (range 29– 78 years), and it was more common in males. According to Ann

Arbor stage, Advanced stage (stage III and IV) was seen in 2 (28.57%). According to the International Prognostic Index (IPI), most (6) were low risk (85.7%). Overall survival ranged from 1–45 months with median OS of 18 months. To conclude, PPL presents more often in early stage and low IPI score. Surgery +/- chemoimmunotherapy with radiotherapy to the parotid is the standard treatment at present.

Keywords

extra nodal, parotid, lymphoma, India

العميق / السطحي، وتم التأكيد بواسطة الكيمياء النسيجية المناعية وذلك في الفترة ما بين يناير 2007 إلى ديسمبر 2012.

اللمفومة النكفية الأولية - مركز السرطان الإقليمي بجنوب الهند

النتائج
كان العمر الناصف 54 عاما (يتراوح المجال 29 - 78 عاما) وكان أكثر شيوعا بين الذكور ، وبناء على تصنيف آن آر بور للمرحلة تم ملاحظة المرحلة المتقدمة (المرحلة 3، 4) في عدد 2 حالة (28.57%) ، وبناء على المنسب المائي الدولي (IPI) كانت الغالبية (6) من ذوي الاختطار المتخفف (85.7%).

اللمفومة النكفية الأولية (PPL) مرض غير اعتيادي ، لذلك فهناك معلومات محدودة عنه بين السكان (جمهرة) الهنود ، ولهذا أجرينا هذه الدراسة الاستيعادية الملاحظة عن اللمفومة النكفية الأولية بمركزنا بجنوب الهند .

وتضمنت هذه الدراسة عدد 7 حالات متتالية شخصت إصابتها باللمفومة النكفية الأولية بواسطة الخزعة النسيجية / الاستئصال النكفية

وتراوح معدل البقيا العامة ما بين 1 - 45 شهرا مع البقيا العامة الناصف مقداره 18 شهرا . ولإيجاز، فإن اللمفومة النكفية الأولية تتجلى غالبا في مرحلة مبكرة وتكون ذات حرز للمنسب المائي الدولي منخفف ، ويكون العلاج الأمثل

Corresponding Author: Venugopal Arroju, MD, OPD-18, Department of Medical Oncology, Kidwai Memorial Institute of Oncology, Dr. MH Marigowda Road, Bangalore- 560029, Karnataka, India.
Tel: 09980707675;
E-mail: venugopalarroje@gmail.com

الكلمات الاساسية : خارج العقدي ، النكفية ،
لمفومة ، الهند .

الحالي يكون بواسطة الجراحة + المعالجة
الكيميائية المناعية مع المعالجة الشعاعية للغدة
النكفية .

Introduction

Primary Parotid lymphoma (PPL) is an unusual entity with an indolent course and better overall survival as compared to other extra nodal lymphomas. It is frequently associated with auto immune diseases such as Sjogren's syndrome. Treatment with radiotherapy and immunochemotherapy are incorporated in the treatment regimens.

Materials and Methods

This was a retrospective observational study done at Kidwai Memorial Institute of Oncology, Bengaluru, a

tertiary care centre in Southern India. All consecutive cases aged 15 years or more, diagnosed as Primary Parotid lymphoma (PPL) by tissue biopsy, confirmed by immunohistochemistry (WHO classification) between January 2007 and December 2012. An informed consent was taken from all the patients and demographic details, clinical details, investigations and treatment details were recorded and analysed.

Evaluation included patient history and physical examination; complete hemogram and serum biochemistry, including lactate dehydrogenase; HIV, HBS-Ag and echocardiography or MUGA scan.

Case No.	Age	Sex	ECOG PS	Stage	Histology	IPI risk	Chemotherapy	RT	Surgery	Outcome
1	52	M	1	IIEA	DLBCL	Low	R-CHOP	-	+	PFS- 38 months OS- 45 months Alive NED
2	40	F	1	IIIEB	NMZL	Low	COP	-	+	OS- 7 months Alive NED
3	78	M	1	IEA	DLBCL	Low	R- CHOP	-	+	LTFU (OS- 1 month)
4	57	M	1	IIEA	DLBCL	Low	R- CHOP	-	+	LTFU (OS - 6 months) NED
5	29	F	1	IVEB	DLBCL	Intermediate	R-CHOP	-	+	LTFU (OS- 24 months) NED
6	57	M	1	IIEA	DLBCL	Low	R-CHOP	-	+	OS- 18 months
7	54	M	1	IEA	DLBCL	Low	CHOP	+	+	OS- 36 months Alive NED

Table 1: Patient characteristics, histology, treatment and outcome

ECOG – Eastern cooperative group IPI: International prognostic index RT– Radiotherapy F– Female; M–Male; R– CHOP: rituximab, cyclophosphamide, hydroxydaunorubicin, oncovin, prednisone. CHOP– cyclophosphamide, hydroxydaunorubicin, oncovin, prednisone; LTFU– lost to follow up; OS– overall survival; NED: no evidence of disease; DLBCL: diffuse large B cell lymphoma :ENMZL: Extranodal marginal zone lymphoma; E– extra nodal; A– absence of B symptoms; B – B symptoms present.

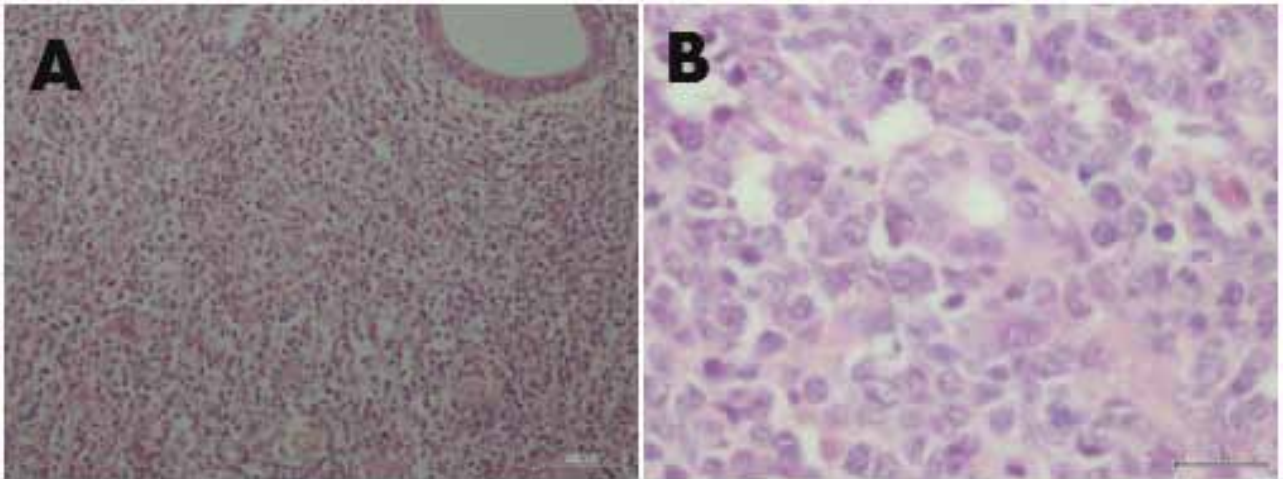


Figure (1A). Uniform neoplastic lymphoid cells infiltrating parotid salivary gland. Normal duct is seen in upper right corner. Hematoxylin and Eosin stain X100. **(1B)** Higher magnification shows large neoplastic cells infiltrating salivary acini. Hematoxylin and Eosin stain X400

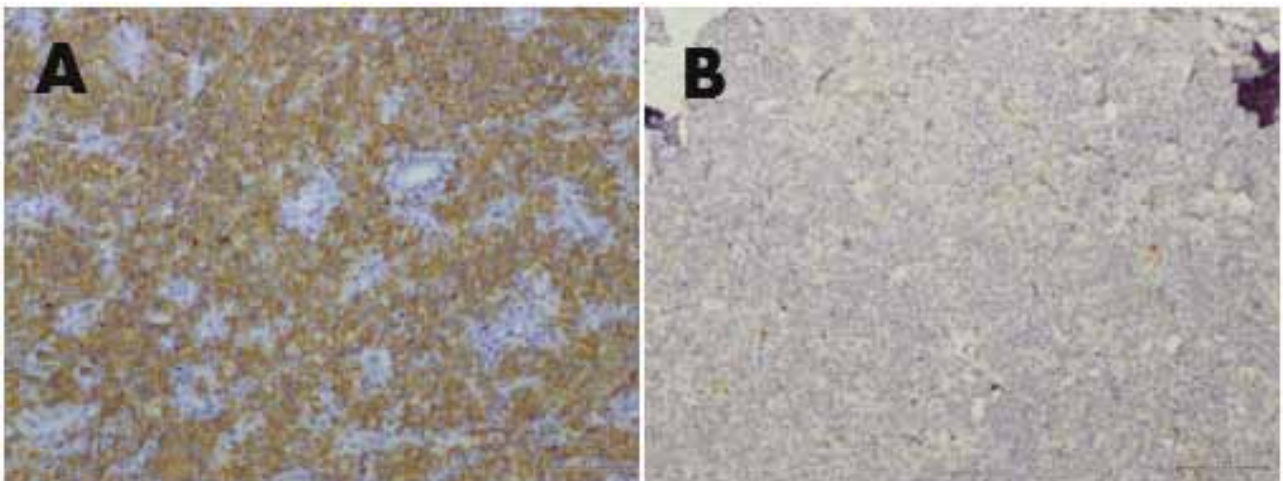


Figure (2A). Neoplastic lymphoid cells with strong expression of the B cell marker CD20 on Immunohistochemistry. Immunoperoxidase stain, HRP polymer method X100. **(2B)** Shows absent expression of CD 3 in neoplastic cells with scattered reactive cells expressing CD 3. Immunoperoxidase stain, HRP polymer method X100.

Computed tomography (CT) scans of chest, abdomen, and pelvis in affordable and chest X-ray/ultrasound abdomen/pelvis in non-affordable patients; bone marrow biopsy from iliac crest. Cerebrospinal fluid (CSF) analysis was done in all cases. Patients were staged according to Ann-Arbor staging as modified by Cotswold's and International prognostic scoring (IPI) was done. All patients either underwent open biopsy/superficial parotidectomy/total parotidectomy for diagnosis. They all received either combination of R-CHOP (rituximab 375mg/m², cyclophosphamide 750mg/m², Adriamycin 50mg/m², vincristine 1.4mg/m² and prednisolone 100mg/d for 5 days) or CHOP or COP.

Radiotherapy was given in 2 patients at a dose of 40 Gy. The responses were assessed according to standard criteria.

Definitions

Hyman and Wolff formulated criteria for the diagnosis of primary parotid gland lymphoma – glandular involvement must be the first clinical manifestation, histologically disease should involve the gland parenchyma, should be confirmed by histopathology and immunohistochemistry.

Statistical Analysis

Median survival was calculated using Microsoft Excel, and overall survival was calculated from diagnosis to the last follow up or death due to any cause.

Results

A total of 7 patients with Primary parotid lymphoma (PPL) were included in the Study (Table 1). Median age was 54 years (29– 78 years), and it was more common in males. B symptoms were seen in 2 out of 7 patients (28.57%). All patients have a good performance status of Eastern co-operative oncology group (ECOG) performance status of 1. The presenting symptom was unilateral parotid enlargement with or without cervical lymph node enlargement. Diffuse large B-cell lymphoma was diagnosed in 6 (Figures 1 and 2) extra nodal marginal zone lymphoma in one. According to Ann Arbor stage, Advanced stage (stage III and IV) were seen in 2 patients (28.57%) and the rest have stage IE or IIE. According to IPI, most ⁽⁶⁾ were in low risk (85.7%) and one patient had intermediate risk score. Overall response rate for the various combination chemotherapies was 5/5 (100%) complete response with R-CHOP, 1 each who received CHOP and COP had complete response. Overall survival ranged from 1–45 months with median OS of 18 months.

Discussion

Though head and neck region is a relatively common site for lymphoma, involvement of Non-Hodgkin's lymphoma in the salivary glands is rather unusual, and accounts for about 5% of all salivary gland neoplasms and around 5% of all extra nodal lymphomas. ⁽¹⁾ Most lymphomas arising in the parotid gland are Non-Hodgkin's lymphoma which are predominantly of the B cell type. ⁽²⁾

Autoimmune disease like Sjogren's syndrome has been well-documented as a predisposing factor. ⁽³⁾ However none of our patients had a pre-existing history suggestive of any autoimmune disease. Majority of the salivary gland lymphomas develop in the parotid gland in view of its large size, rich lymphoid tissue and presence of intraparotid lymph nodes. ⁽⁴⁾

Hyman and Wolff formulated a criteria for the diagnosis of primary parotid gland and lymphoma glandular involvement must be the first clinical manifestation, histologically, the disease should involve the gland parenchyma, lymphoma should be confirmed by histopathology and immunohistochemistry. ⁽⁵⁾ All seven patients satisfied the criteria that was put forward by Hyman and Wolff.

Most cases of primary parotid lymphomas are of indolent type with Mucosa associated lymphoid tissue (MALT) being the most common type. Various authors have suggested that autoimmune diseases predispose to MALT. However, in our series, six had diffuse large B cell lymphoma (DLBCL) and one had extra nodal marginal zone lymphoma (ENMZL). ⁽⁶⁾

Various histologies of salivary gland lymphoma including follicular lymphoma, DLBCL and MALT have been reported with MALT being the most common type. ⁽⁷⁾ In other series, the median age of presentation was 50–70 years and in our series too had a similar age of presentation with a median of 54 years. ^(7, 8) Kojima et al reported 30 cases of salivary gland lymphoma in which the median age of presentation was 57 years. ⁽⁸⁾ The incidence in males was more as compared to females which was also seen in our series. ⁽⁹⁾ Most patients present with a unilateral painless swelling over the parotid region with an acute or sub-acute presentation of few weeks to months. ⁽¹⁰⁾ The patients usually have an indolent behaviour with most presenting with an early stage of IE or IIE (Ann Arbor staging) with B symptoms being uncommon. ⁽⁸⁾ A similar finding was found in our patients with 28.57% of our patients presenting with B symptoms. All seven patients in our series had an Eastern Co-operative oncology group (ECOG) performance status of 1. Two of our patients have advanced stage of presentation (Stage III/ IV). Computed tomography scan of the neck was widely used for aiding in diagnosis. Extent of the disease and differentiating benign and malignant lesions were possible in around 85% of the cases with CT scan. ⁽¹¹⁾ In PPL with intermediate/high grade histology, international prognostic index (IPI) has correlated with outcome. ⁽¹²⁾ In our study, all but one have a low IPI risk score. All our patients underwent an open biopsy/superficial parotidectomy/deep parotidectomy for diagnosis. They were all treated with anthracycline based regimens in combination

with rituximab except in two patients here rituximab couldn't be used in view of financial constraints. Radiotherapy was used only in two patients. ⁽¹³⁾ In various other series, surgery was generally employed for diagnosis in order to satisfy the criteria of primary parotid lymphoma (parotid parenchyma should be present in the specimen). A combination of chemotherapy (R-CHOP/CHOP) and radiotherapy have been used to treat these patients. In the current series, the median survival was 18 months (range 1–45 months). Certain low grade lymphomas of the parotid with early stage have been treated with only radiotherapy with good local control. ⁽¹⁴⁾ The use of rituximab based chemotherapy for extranodal disease is based on the MabThera International Trial (MINT) trial which included 75% of patients in early stage and 33% extra nodal (EN) disease, randomized between six cycles of CHOP and six cycles of R-CHOP, and radiation for patients with bulky or EN disease at presentation. It showed a significant benefit in long term survival with the addition of rituximab to chemotherapy in young patients. ⁽¹⁵⁾

Acknowledgement

The authors would like to thank all the staff and students of the Department of Medical Oncology, Surgical Oncology and Pathology for their support in preparing this manuscript.

References

1. Barnes L, Myers EN, Prokopakis EP. Primary malignant lymphoma of the parotid gland. *Arch Otolaryngol Head Neck Surg* 1998;124:573–577.
2. Hanna E, Wanamaker J, Adelstein D, Tubbs R, Lavertu P. Extranodal lymphomas of the head and neck: A 20 year experience. *Arch Otolaryngol Head Neck Surg* 1997;123:1318–1323.
3. Nichols RD, Roebuck JW, Sullivan JC. Lymphoma and the parotid gland. *Laryngoscope* 1982; 92: 365–369.
4. Batsakis JG. Primary lymphomas of the salivary glands. *Ann Otol Rhinol Laryngol* 1986;95:107–8.
5. Shikhani A, Samara M, Allam C, Salem P, Lenhard R. Primary lymphoma in the salivary glands: report of five cases and review of the literature. *Laryngoscope* 1987;97(12):1438–42.
6. Nime FA, Cooper HS, Eggleston JC. Primary malignant lymphomas of the salivary glands. *Cancer* 1976;37(2):906–12.
7. Gleeson MJ, Bennett MH, Cawson RA. Lymphomas of salivary glands. *Cancer* 1986;58(3):699–704.
8. Kojima M, Shimizu K, Nishikawa M, Tamaki Y, Ito H, Tsukamoto N, Masawa N. Primary salivary gland lymphoma among Japanese: A clinicopathological study of 30 cases. *Leuk Lymphoma* 2007;48(9):1793–8.
9. Takahashi H, Tsuda N, Tezuka F, Fujita S, Okabe H. Non-Hodgkins lymphomas of the major salivary gland: a morphologic and immunohistochemical study of 15 cases. *J Oral Pathol Med* 1990;19(7):306–12.
10. Loggins JP, Urquhart A. Preoperative distinction of parotid lymphomas. *J Am Coll Surg* 2004;199:58–61.
11. Urquhart A, Hutchins LG, Berg RL. Preoperative computed tomography scans for parotid tumour evaluation. *Laryngoscope* 2001;111:1984–1988.
12. Sarris AH, Papadimitrakopoulou V, Dimopoulos MA, Smith T, Pugh W, et al. Primary parotid lymphoma: the effect of International Prognostic Index on outcome. *Leuk Lymphoma* 1997;26(1):49–56.
13. Wilder RB, Jones D, Tucker SL, Fuller LM, Ha CS, McLaughlin P, et al. Long-term results with radiotherapy for stage I–II follicular lymphomas. *Int J Radiat Oncol Biol Phys* 2001;51(5):1219–27.
14. Mehle ME, Kraus DH, Wood BG, Tubbs R, Tucker HM, Lavertu P. Lymphoma of the parotid gland. *Laryngoscope*. 1993;103(1 Pt 1):17–21.
15. Pfreundschuh M, Kuhnt E, Trümper L, Osterborg A, Trneny M, Shepherd L, Gill DS, et al. CHOP-like chemotherapy with or without rituximab in young patients with good-prognosis diffuse large-B-cell lymphoma: 6-year results of an open-label randomized study of the MabThera International Trial (MINT) Group. *Lancet Oncol* 2011;12: 1013–1022.