

# A Case of Concurrent Multiple Sclerosis and Celiac Disease

Zahra Azizi<sup>1</sup>, NaserEbrahimi Daryani<sup>2</sup>, Maryam Rezaii Salim<sup>3</sup>, SanamJavid Anbardan<sup>4</sup>

<sup>1</sup> Iran University of Medical Sciences, Tehran, Iran

<sup>2</sup> Department of Internal Medicine, Division of Gastroenterology, Imam Khomeini Hospital, Tehran University of Medical Sciences, Tehran, Iran

<sup>3</sup> Private gastroenterology clinic, Tehran, Iran

<sup>4</sup> Tehran University of Medical Sciences, Tehran, Iran

## ABSTRACT

Multiple sclerosis (MS) is an autoimmune inflammatory process that affects the central nervous system (CNS). Celiac disease (CD) is a systemic autoimmune disorder of gluten intolerance. Based on the presumed association of MS with multiple autoimmune processes, the coincidence of MS with gluten sensitivity has been investigated with controversial results.

Here, we report a known case of MS with mild gastrointestinal symptoms and spontaneous abortions. Thorough paraclinical evaluations revealed iron deficiency anemia and high titers of tissue transglutaminase antibody (tTG). A small bowel biopsy demonstrated changes compatible with CD, MARS type 3c. Based on the serologic results and biopsy findings, a diagnosis of CD was established and the patient was instructed to consume a gluten-free diet. Gastrointestinal symptoms abated and her serum levels of tTG normalized, along with improvement in the patient's iron profile during follow ups.

The combined presence of MS and CD is a rare situation for which previous studies have failed to clarify the existence of any correlation between MS and CD. Thus, further investigation of CD in MS patients with gastroenterological complaints is recommended.

**Keywords:** Multiple sclerosis; Celiac disease; Autoimmune diseases

*please cite this paper as:*

Azizi Z, Ebrahimi Daryani N, Rezaii Salim M, Javid Anbardan S. A Case of Concurrent Multiple Sclerosis and Celiac Disease. *Govaresh* 2013;18:

## INTRODUCTION

Multiple sclerosis (MS) is a chronic autoimmune inflammatory process affecting the central nervous system (CNS) that results from destruction of

myelin and axons as a consequence of unknown etiology. It appears mostly in adult females(1,2). Approximately 80% of MS cases are the relapsing-remitting form (RRMS) with episodes of neurological dysfunction and remission. According to autoimmune characteristics, this disease is effectively controlled by administration of immunosuppressive agents(3-6). The diagnosis of MS is based on the association of clinical manifestations and abnormalities visualized on magnetic resonance imaging (MRI) studies and cerebrospinal fluid analysis(2).

Celiac disease (CD) is a systemic autoimmune disorder characterized by gluten intolerance in genetically predisposed individuals(3,7-9). In addition

### Corresponding author:

Sanam Javid Anbardan, MD

Tehran University Of Medical Sciences Tehran, Iran

Tel: +98 21 88793896

Fax:+98 21 88799840

E-mail: sanam.javid@gmail.com

Received: 18 Dec. 2013

Edited: 29 Jan. 2014

Accepted: 30 Jan. 2014

to enteropathy, numerous extra-intestinal signs including neurologic manifestations such as ataxia, neuropathy, epilepsy and white-matter lesions have been identified as an accompaniment to CD(4,10,11). Although high serum levels of tissue transglutaminase antibody (tTG) antibody is highly sensitive and specific for the diagnosis of CD, diagnosis is established in suspected individuals by the presence of typical lesions on small bowel biopsy(12,13).

Considering the possibility of concurrent MS with other autoimmune processes, multiple studies have investigated the association of MS with gluten sensitivity(14-16). Currently, controversial data are available about efficacy of a gluten free diet in alleviating MS manifestations, which necessitates additional studies(10).

Here, we describe the case of an RRMS patient who simultaneously presented with CD.

#### CASE REPORT

A 39-year-old female, who was a known case of MS presented to our clinic during the past year with complaints of abdominal pain, flatulence, anorexia and nausea. The patient's MS was diagnosed according to McDonald's criteria(17)four years prior after the occurrence of multiple, recurrent episodes of diplopia and blurred vision (Figure 1).

At presentation, her symptoms were controlled by weekly injections of interferon beta 1a and daily administration of gabapentin and amantadine. Additionally, she had experienced two spontaneous abortions during this period which were of unknown etiology despite comprehensive gynecological work up.

Her gastrointestinal symptoms initiated three months prior to her attendance in our clinic. On physical examination, no abnormality was detected except for pallor of the conjunctiva and mucosal surfaces. Considering concomitance of gastrointestinal manifestations and recurrent abortions, an exhaustive paraclinical evaluation was performed.

Laboratory findings demonstrated iron deficiency anemia (hemoglobin: 11.1(g/dl), mean corpuscular volume (fL): 74.3, ferritin (ng/ml): 6.39, and total iron binding capacity: 489) and high titers of tTG (tTG: 161.5 U/ml, normal<12 U/ml).

An upper endoscopy with small bowel biopsy was performed which showed no apparent lesion or abnormality (Figure 2). However, greater than 30 intraepithelial lymphocytes (IELs) per 100 enterocytes, total villous atrophy and crypt hyperplasia were

evident on histologic evaluation of the obtained biopsy specimen - a finding consistent with CD, MARSH type 3c (flat destructive).

Based on the concordance between the serologic results and the biopsy findings, the patient was diagnosed with CD and advised to consume a gluten-free diet.

During follow ups, the patient demonstrated improvement of gastrointestinal manifestations and normalization of her serum tTG levels. The latest recorded serum level of tTG was 1 U/ml. Her iron profile showed improvement, but not complete recovery. The laboratory values from prior and post-treatment are shown in Table 1. Complementary laboratory information is seen in Table 2.

#### DISCUSSION

MS is a chronic disabling neurological disorder affecting 1% of the population worldwide, mostly young females. It is assumed to be an autoimmune demyelinating process that impacts the CNS via poorly understood mechanisms(3,18). The simultaneous presentation of MS with other autoimmune disorders has been demonstrated previously(19).

CD or gluten sensitive enteropathy, is a chronic systemic autoimmune disorder resulting from amplified immunological sensitivity to gluten proteins in genetically susceptible individuals. Along with enteropathy, diverse extra-intestinal manifestations including neurologic, dermatologic and other autoimmune disorders accompany CD(3,13,20-23).

Although CD commonly presents as the classic diarrhea-predominant form with fatigue, weight loss, diarrhea, bloating and anemia(13), the prevalence of atypical forms associated with numerous extra-intestinal manifestations that lack gastrointestinal symptoms have recently increased(9,24,25).

Although the association of CD with MS has been described as case reports with a small number of patients, their relationship is a controversial topic in the medical literature(26-28).

A study from Norway has reported significantly higher serum levels of anti-gliadin antibodies (AGA) in the MS group compared to a control group(29). In contrast, in a study conducted by Borhani et al., no significant differences in serum levels of AGA were detected between MS patients and normal controls(30). Although a study from Israel revealed a significant increase in AGA and tTG titers in MS patients, the measures were not significantly higher compared to the control group(31). Finally, in a study performed by

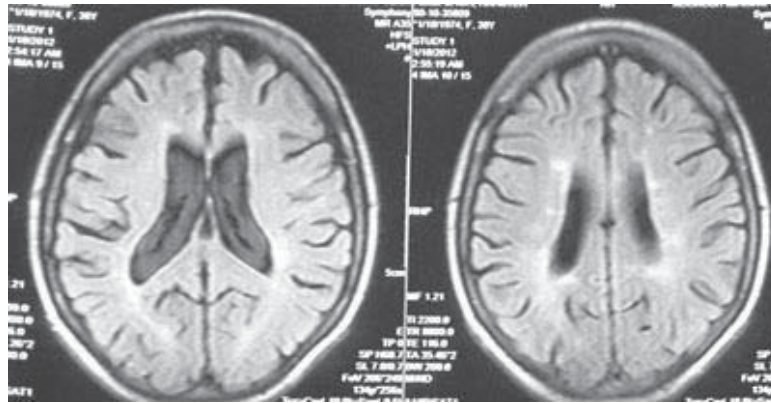


Fig. 1: Brain MRI demonstrating multiple periventricular white matter plaques.

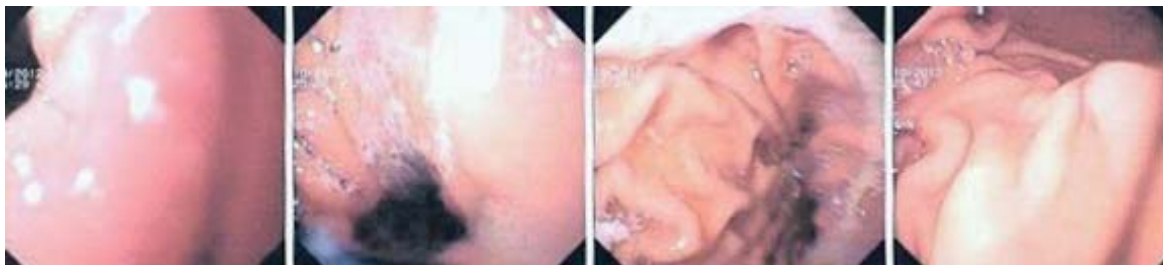

Fig. 2: Upper endoscopy of the patient demonstrating no apparent abnormality.

Table 1: Paraclinical values prior to and post-treatment.

	Prior to treatment	Post-treatment
tTG (U/ml)	161.5	1
Hemoglobin(g/dl)	10.7	11
MCV (fl)	78.8	73.9
MCH(pg)	24	23.5
Serum iron(µg/dl)	27	36
Ferritin (ng/ml)	6.39	10 (10-120)
Total iron binding capacity (TIBC)( µg/dl)	489	400 (280-420)
Platelets (/ml)	252000	324000

Rodrigo et al., high serum levels of tGt-2 antibodies were observed in RRMS patients and their first-degree relatives compared to healthy controls. This study failed to report the role of serological gluten markers in the pathogenesis of MS(3).

Currently, we described a case of concurrent MS and CD. Thus, iron deficiency anemia and recurrent abortions observed in our patient could be attributed to untreated CD.

Although T cell-mediated immunity is considered to be responsible for both MS and CD, the concurrent

presence of the aforementioned conditions is rare. Accordingly, it is recommended to assess gluten sensitivity in MS patients who present with gastrointestinal manifestations.

Additional investigations are required considering the failure of previous studies to disclose any significant association between MS and gluten sensitive enteropathy, in addition to the lack of conclusive evidences that support an increased frequency of CD among patients with MS(4,32).

**Table 2: Complementary laboratory evaluations.**

Immunologic markers		Viral markers		Biochemistry	
Fasting blood glucose(FBS,mg/dl)	93	Hepatitis C virus(HCV) Antibody	Negative	Anticardiolipin Antibody (IgG)	Negative
Anti-cardiolipin	24	Human immunodeficiency virus (HIV) test	Negative	Antibody(IgM)	Negative
Creatinine(mg/dl)	0.6	Hepatitis B virus surface antigen (HBs Ag)	Negative	Rubella IgG	reactive
Uric acid (mg/dl)	2.6			Rubella IgM	non-reactive
Cholesterol(mg/dl)	81			Toxoplasma IgG	reactive
LDL- cholesterol(mg/dl)	113.5			Toxoplasma IgM	non-reactive
HDL-cholesterol(mg/dl)	46			Cytomegalovirus (CMV)IgG	reactive
Calcium (mg/dl)	9			Cytomegalovirus (CMV)IgM	non-reactive
Phosphorus( mg/dl)	2.9				
Na (mEq/L)	138				
K(mEq/L)	4.8				
Alkaline phosphatase (IU/L)	175				
Alanine transaminase(ALT,IU/L)	15				
Aspartate transaminase (ASL,IU/l)	20				
Partial thromboplastin time (second)	35				
Hormonal panel		Urine Analysis		Stool exam	
Thyroid stimulating hormone (TSH,mIU/ml)	1.8	White blood cell (WBC,number/ high power field)	0-1	Occult blood(OB)	Negative
T4(mIU/ml)	7.6	Red blood cell (RBC,number /high power field)	0-1	White blood cell(WBC)	Negative
Prolactin(ng/ml)	15.7	Cast	none	Red blood cell(RBC)	Negative
Follicular Stimulating Hormone (FSH,mIU/ml)	5				
Luteal hormone (LH,mIU/ml)	2.2				
Estradiol(pg/ml)	66.3				

## REFERENCES

1. Goldenberg MM. Multiple sclerosis review. *P T* 2012;37:175-84.
2. Olek M. Epidemiology, risk factors and clinical features of multiple sclerosis in adults. UpToDate, Gonzalez-Scarano, F (Ed), UpToDate, Waltham, MA. 2010.
3. Rodrigo L, Hernandez-Lahoz C, Fuentes D, Alvarez N, Lopez-Vazquez A, Gonzalez S. Prevalence of celiac disease in multiple sclerosis. *BMC Neurol* 2011;11:31.
4. Shaygannejad V, Ghasemi M, Mirmohamadsadeghi M. Multiple sclerosis or neurological manifestations of Celiac disease. *Adv Biomed Res* 2013;2:38.
5. Carroll WM. Oral therapy for multiple sclerosis--sea change or incremental step. *N Engl J Med* 2010;362:456-8.
6. Tsutsui S, Stys PK. Degeneration versus autoimmunity in multiple sclerosis. *Ann Neurol* 2009;66:711-3.
7. James MW, Scott BB. Coeliac disease: the cause of the various associated disorders? *Eur J Gastroenterol Hepatol* 2001;13:1119-21.
8. Rodrigo L. Celiac disease. *World J Gastroenterol* 2006;12:6585-93.
9. Green PH, Cellier C. Celiac disease. *New Engl J Med* 2007;357:1731-43.
10. Hadjivassiliou M, Sanders DS, Grünewald RA, Woodroffe N, Boscolo S, Aeschlimann D. Gluten sensitivity: from gut to brain. *Lancet Neurol* 2010;9:318-30.
11. Hernandez L, Green PH. Extraintestinal manifestations of celiac disease. *Curr Gastroenterol*

- Rep* 2006;8:383-9.
12. Rewers M. Epidemiology of celiac disease: what are the prevalence, incidence, and progression of celiac disease? *Gastroenterology* 2005;128:S47-51.
  13. Rashtak S, Murray J. Review article: coeliac disease, new approaches to therapy. *Aliment Pharmacol Ther* 2012;35:768-81.
  14. Zelnik N, Pacht A, Obeid R, Lerner A. Range of neurologic disorders in patients with celiac disease. *Pediatrics* 2004;113:1672-6.
  15. Ludvigsson JF, Olsson T, Ekblom A, Montgomery SM. A population-based study of coeliac disease, neurodegenerative and neuroinflammatory diseases. *Aliment Pharmacol Ther* 2007;25:1317-27.
  16. Grossman G. Neurological complications of coeliac disease: what is the evidence? *Pract Neurol* 2008;8:77-89.
  17. Polman CH, Reingold SC, Banwell B, Clanet M, Cohen JA, Filippi M, et al. Diagnostic criteria for multiple sclerosis: 2010 revisions to the McDonald criteria. *Ann Neurol* 2011;69:292-302.
  18. Fromont A, Binquet C, Sauleau EA, Fournel I, Bellisario A, Adnet J, et al. Geographic variations of multiple sclerosis in France. *Brain* 2010;133:1889-99.
  19. Batur-Caglayan HZ, Irkeç C, Yildirim-Capraz I, Atalay-Akyurek N, Dumlu S. A case of multiple sclerosis and celiac disease. *Case Rep Neurol Med* 2013;2013:576921.
  20. Hernández-Lahoz C, Rodríguez S, Tuñón A, Saiz A, Santamarta E, Rodrigo L. [Sustained clinical remission in a patient with remittent-recurrent multiple sclerosis and celiac disease gluten-free diet for 6 years]. *Neurologia* 2009;24:213-5.
  21. Feighery C. Fortnightly review: coeliac disease. *BMJ* 1999;319:236-9.
  22. Leeds JS, Hopper AD, Sanders DS. Coeliac disease. *Br Med Bull* 2008;88:157-70.
  23. Tursi A, Giorgetti GM, Iani C, Arciprete F, Brandimarte G, Capria A, et al. Peripheral neurological disturbances, autonomic dysfunction, and antineuronal antibodies in adult celiac disease before and after a gluten-free diet. *Dig Dis Sci* 2006;51:1869-74.
  24. Roma E, Panayiotou J, Karantana H, Constantinidou C, Siakavellas SI, Krini M, et al. Changing pattern in the clinical presentation of pediatric celiac disease: a 30-year study. *Digestion* 2009;80:185-91.
  25. Nejad MR, Rostami K, Pourhoseingholi MA, Mojarad EN. Atypical Presentation is Dominant and Typical for Coeliac. *J Gastrointest Liver Dis* 2009;18:285-91.
  26. Ferrò MT, Franciotta D, Riccardi T, D'Adda E, Mainardi E, Montanelli A. A case of multiple sclerosis with atypical onset associated with autoimmune hepatitis and silent coeliac disease. *Neurol Sci* 2008;29:29-31.
  27. Frisullo G, Nociti V, Iorio R, Patanella AK, Marti A, Cammarota G, et al. Increased expression of T-bet in circulating B cells from a patient with multiple sclerosis and celiac disease. *Hum Immunol* 2008;69:837-9.
  28. Phan-Ba R, Lambinet N, Louis E, Delvenne P, Tshibanda L, Boverie J, et al. Natalizumab to kill two birds with one stone: A case of celiac disease and multiple sclerosis. *Inflamm Bowel Dis* 2011;17:E62-3.
  29. Reichelt KL, Jensen D. IgA antibodies against gliadin and gluten in multiple sclerosis. *Acta Neurol Scand* 2004;110:239-41.
  30. Borhani Haghighi A, Ansari N, Mokhtari M, Geramizadeh B, Lankarani KB. Multiple sclerosis and gluten sensitivity. *Clin Neurol Neurosurg* 2007;109:651-3.
  31. Shor DBA, Barzilai O, Ram M, Izhaky D, Porat-Katz BS, Chapman J, et al. Gluten Sensitivity in Multiple Sclerosis. *Ann N Y Acad Sci* 2009;1173:343-9.
  32. Nicoletti A, Patti F, Fermo SL, Sciacca A, Laisa P, Liberto A, et al. Frequency of celiac disease is not increased among multiple sclerosis patients. *Mult Scler* 2008;14:698-700.