

## CASR REPORT

## Third Ventricle Colloid Cyst as a Cause of Sudden Drop Attacks of a 13-Year-Old Boy

Behzad Zohrevandi, Vahid Monsef Kasmaie\*, Payman Asadi, Hosna Tajik

Guilan Road Trauma Research Center, Guilan University of Medical Sciences, Rasht, Iran

\*Corresponding Author: Vahid Monsef Kasmaie; Road trauma Research Center, Guilan University of Medical Sciences, Rasht, Iran.

Tel: +989113344071. Fax: +981313238373; Email: vmonsef@yahoo.com

Received: December 2014; Accepted: December 2014

### Abstract

Colloid cysts are mucous-filled masses with an outer fibrous layer. These cysts are rare developmental malformation and not a true neoplasm. They usually found incidentally and are asymptomatic; but in some cases may associate with rapid neurologic deterioration, herniation, and sudden death. Recognition of this rare but important diagnosis may result in decreasing mortality. In this report, we presented a 13-year-old boy with complaint of two times drop attack and final diagnosis of colloid cyst in the third brain ventricle.

**Key words:** Colloid cyst; sudden death; hydrocephalus

**Cite This Article as:** Zohrevandi B, Kasmaie BM, Asadi P, Tajic H. Third ventricle colloid cyst as a cause of sudden drop attacks of a 13-year-old boy. *Emergency*. 2015;3(4):162-4.

### Introduction:

Colloid cysts are mucous-filled masses with an outer fibrous layer. These cysts are rare developmental malformation and not a true neoplasm. They are congenital benign tumor accounting for 15-20% of intraventricular mass but only about 1% of intracranial ones (1-3). They can be diagnosed at any age but usually become symptomatic in the third to sixth decades and more common in men than women. They usually found incidentally and are asymptomatic; but in some instances may associate with rapid neurologic deterioration, herniation, and sudden death. So, recognition of this rare but important diagnosis may result in decreasing mortality (4). In this report, we presented a 13-year-old boy with complaint of two times drop attack and final diagnosis of colloid cyst in the third brain ventricle.

### Case Report:

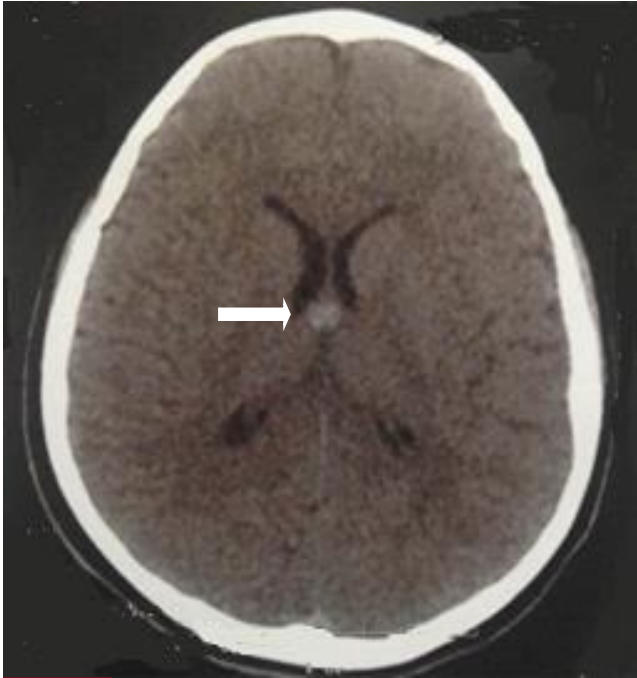
A 13-year-old boy was brought to the emergency department (ED) with complaint of two times drop attack. The patient mentioned that he felt sudden weakness in both lower limbs, which led to drop. He did not lose his consciousness before, during, or after dropping. These attacks were happened about 4 hours before admission and he did not have any same experience previously. He did not have complaint of nausea, vomiting, headache, vertigo, blurred vision, or palpitation. The subject did not have any known structural or congenital heart disease, but suffered from asthma and used salbutamol spray irregularly. The patient did not have trauma his-

tory and there was no positive history of any known medical illness in his parents or closed relatives. On arrival, he had 36.9°C axillary temperature, 16/minute respiratory rate, 90/minute pulse rate, 120/80 mmHg blood pressure, and 96% oxygen saturation at room air. On physical examination, he did not have focal neurologic findings or even paresthesia or paraplegia. General examination of head and neck, chest, abdomen, and limbs did not reveal any positive findings. An electrocardiogram (ECG) showed normal sinus rhythm without any obvious abnormality. All biochemistry parameters were reported as normal range. Following the evaluation process, a brain computed tomography (CT) was performed (Figure-1). A hyperdense round lesion was seen in the third ventricle consequently caused that the corresponding physician requested a neurologic consultation in the ED. Finally, the brain magnetic resonance imaging (MRI) confirmed the diagnosis of third ventricle colloid cyst and the patient was underwent surgery and discharged without any problem (Figure 2).

### Discussion:

The colloid cysts commonly settle near the foramen of Monro in the anterior third ventricle and so may encounter with drainage of the cerebrospinal fluid (CSF) (3). Since even a small lesion can block the mentioned foramen, these cysts may result in hydrocephalus and increase the intra cranial pressure (5). Increased intracranial pressure can be manifested with headache

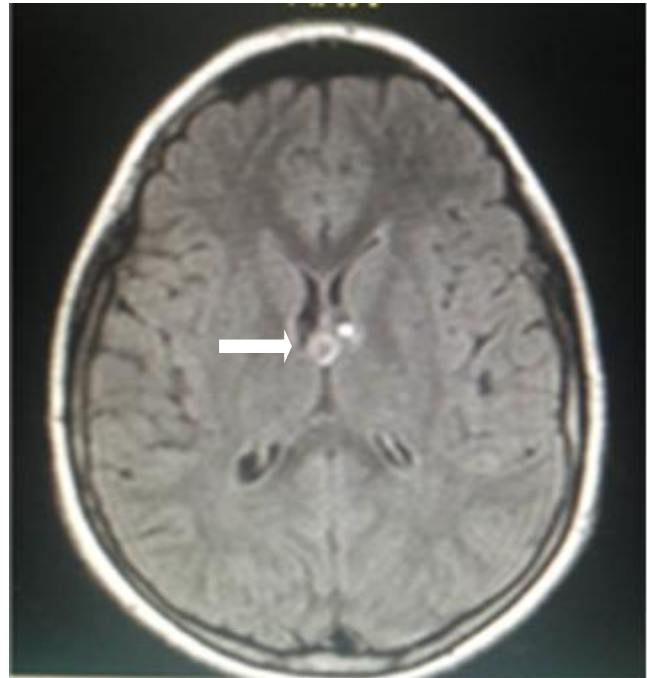




**Figure 1:** Axial brain computed tomography

described as severe and intermittent, with short duration, usually located frontally.

In contrast with usual headaches, secondary to intracranial tumors, the colloid cyst induced headache can be relieved by lying down (4). Other symptoms include drop attacks, gait abnormalities, progressive dementia, and transient loss of consciousness. In children, the most common symptoms are nausea, vomiting, headache, diplopia, and papilledema (6). The classic clinical description of intermittent headaches and drop attacks occurs in only one-third of patients. Sudden obstruction of the ventricular system and following rapid rising of intracranial pressure can lead to herniation and rarely sudden death (7, 8). Colloid cysts size varies from 3-40 millimeters in diameter, but the size do not related to their symptoms or outcome, as even small ones may lead to sudden death (9). Colloid cyst is usually diagnosed by non-contrast computed tomography (CT) as an oval or rounded hyperdense mass on the anterior aspect of the third ventricle. They may occasionally be hypodense or isodense to the brain, or found in other areas of the brain. Colloid cysts have different manifestation on MRI. Despite their variable signal characteristics, their location and shape help to the correct pre-operative diagnosis in most patients (6). Half of the cases are hyperintense on T1-weighted MRI images and hypointense on T2-weighted MRI images respected to brain. Isointense cysts are not easily identified on MRI,



**Figure 1:** FLAIR sequences of brain magnetic resonance imaging

and in such instances CT scan is more useful (9, 10). Early detection and excision of the colloid cyst carry the best prognosis. Surgical excision is curative but challenging due to its location. Small asymptomatic colloid cyst can be considered for close follow up by serial examinations and neuroimaging (11). There is also the rare report of spontaneous resolving of the third ventricle colloid cyst (12, 13).

**Acknowledgments:**

None

**Conflict of interest:**

None

**Funding support:**

None

**Authors' contributions:**

All authors passed four criteria for authorship contribution based on recommendations of the International Committee of Medical Journal Editors.

**References:**

1. Humphries RL, Stone CK, Bowers RC. Colloid cyst: A case report and literature review of a rare but deadly condition. *J Emerg Med.* 2011;40(1):e5-e9.
2. Uhlmann EJ, Norden AD. Rare Tumors. Primary Central Nervous System Tumors: Springer; 2011. p. 499-528.
3. Ho-Fung V, Jaimes C, Pollock AN. Third Ventricular Colloid Cyst. *Pediatr Emerg Care.* 2011;27(3):242-3.
4. Spears RC. Colloid cyst headache. *Curr Pain Headache Rep.* 2004;8(4):297-300.
5. Symss NP, Ramamurthi R, Kapu R, et al. Complication avoidance in transcallosal transforaminal approach to colloid



cysts of the anterior third ventricle: An analysis of 80 cases. *Asian J Neurosurg.* 2014;9(2):51-7.

6. Armao D, Castillo M, Chen H, Kwock L. Colloid cyst of the third ventricle: imaging-pathologic correlation. *Am J Neuroradiol.* 2000;21(8):1470-7.

7. Black M, Graham D. Sudden unexplained death in adults caused by intracranial pathology. *J Clin Pathol.* 2002;55(1):44-50.

8. Ravnik J, Bunc G, Grcar A, Zunic M, Velnar T. Colloid cysts of the third ventricle exhibit various clinical presentation: a review of three cases. *Bosn J Basic Med Sci.* 2014;14(3):132-5.

9. Mamourian AC, Cromwell LD, Harbaugh RE. Colloid cyst of the third ventricle: sometimes more conspicuous on CT than MR. *Am J Neuroradiol.* 1998;19(5):875-8.

10. Maeder PP, Holtås S, Basibüyük L, Salford LG, Tapper U, Brun A. Colloid cysts of the third ventricle: correlation of MR and CT findings with histology and chemical analysis. *Am J Neuroradiol.* 1990;11(3):575-81.

11. Desai KI, Nadkarni TD, Muzumdar DP, Goel AH. Surgical management of colloid cyst of the third ventricle—a study of 105 cases. *Surg Neurol.* 2002;57(5):295-302.

12. Annamalai G, Lindsay K, Bhattacharya J. Spontaneous resolution of a colloid cyst of the third ventricle. *Br J Radiol.* 2008 81(961):e20-2.

13. Alnaghmoosh N, Alkhani A. Colloid cysts in children, a clinical and radiological study. *Childs Nerv Syst.* 2006;22(5):514-6.

