

## Case Report

# Successful management of bilateral refractory chylothorax after double lung transplantation for lymphangiomyomatosis

Mohammed Hussein<sup>1,2</sup>, Yasser M. Aljehani<sup>1</sup>, Imran Nizami<sup>1</sup>, Waleed Saleh<sup>1</sup>

<sup>1</sup>Department of Surgery, King Faisal Specialist Hospital & Research Center, Riyadh, Saudi Arabia, <sup>2</sup>Department of Cardiothoracic Surgery, Ain Shams University, Cairo, Egypt

### Address for correspondence:

Dr. Yasser M. Aljehani,  
Department of Surgery,  
King Faisal Specialist  
Hospital & Research  
Center, Riyadh,  
Saudi Arabia.  
E-mail: [altahlawi@yahoo.com](mailto:altahlawi@yahoo.com)

Submission: 05-09-2013  
Accepted: 11-01-2014

### Access this article online

Quick Response Code:



Website:  
[www.thoracicmedicine.org](http://www.thoracicmedicine.org)

DOI:  
10.4103/1817-1737.128862

### Abstract:

Lymphangiomyomatosis (LAM) is a rare disease that leads to airways and lymphatic channels obstruction due to abnormal smooth muscle proliferation. It presents with dyspnea, pneumothorax or chylothorax. Lung transplantation (LT) has emerged as a valuable therapeutic option with limited reports. We report a case of LAM that underwent double LT and complicated by refractory bilateral chylothorax which was managed successfully by povidone-iodine pleurodesis and the addition of sirolimus to the post-transplantation immunosuppressive therapy. The patient has no recurrence with 24 months follow-up.

### Key words:

Chylothorax, lung transplantation, lymphangiomyomatosis, pleurodesis, povidone iodine

Lymphangiomyomatosis (LAM) is a rare disease characterized by the proliferation of abnormal smooth-muscle cells leading to obstruction of airways and lymphatics (e. g.: Chylous pleural and peritoneal effusions) predominantly affecting women during the childbearing age. Lung transplantation (LT) has emerged as a viable treatment option for patients with end-stage LAM.<sup>[1,2]</sup> Common respiratory presentations are dyspnea, pneumothorax and chylothorax. Chylothorax is defined as a pleural effusion with triglyceride level >110 mg/dl or the presence of chylomicrons in the fluid. Chylothorax usually results from obstruction or disruption of the thoracic duct or its tributaries. Chylothorax can occur in 8-30% of cases of LAM or as a complication after LT.<sup>[3]</sup> Management of chylothorax in these patients is difficult and not well-defined.<sup>[1]</sup> Improper or delayed management of post-transplant chylothorax can lead to unsuccessful transplant outcome.<sup>[4]</sup>

Standard therapeutic options including dietary regimens containing medium-chain triglycerides, chest tube drainage and thoracic duct ligation have been successful in managing chylothorax in lung transplant recipients with LAM.<sup>[3]</sup>

In the present case, chemical pleurodesis using sterile diluted povidone iodine and adding sirolimus to the immunosuppressive therapy successfully controlled post-transplant recurrent

chylous effusion after failure of above mentioned conventional therapies.

### Case Report

In June 2011 a 31-year-old female patient presented with severe progressive dyspnea and respiratory failure, requiring O<sub>2</sub> therapy due to end-stage LAM with no extra-pulmonary manifestations. She was referred to our center for LT work-up. A high resolution computed tomography showed honeycombing pattern with multiple thin-walled cysts diffusely distributed in both lungs and mild right-sided pleural effusion [Figure 1]. At the time of listing in the transplant program, she had severely limited pulmonary reserve with pulmonary function studies showing a decline of forced expiratory volume in 1 s (FEV<sub>1</sub>) (0.91 l, 25% of predicted), restrictive respiratory capacity, vital capacity (1.74 l, 48% of predicted) and decrease of diffusion capacity of the lung for carbon monoxide (2.5 mmol/min/kPa, 28% of predicted).

The clinical and radiological features were suggestive for LAM and the patient was listed for LT [Figure 1].

In August 2011, the patient underwent bilateral LT and a moderate amount of chylous effusion was found in the right hemithorax. The right lung was transplanted without cardiopulmonary

bypass. Cardiopulmonary bypass was used during the left lung transplant due to hemodynamic instability. Thoracic duct mass ligation was done at the end of the operation. No intra-operative complications were recorded and on the post-operative day 4 the patient was breathing spontaneously. On the 9<sup>th</sup> post-operative day, she was discharged from the intensive care unit. Since the 1<sup>st</sup> post-operative day a significant amount (>800 ml/day) of pleural fluid drainage was observed from the right chest tube. When the patient started with enteral nutrition the fluid showed an evident conversion to chylous effusion on the same side with a significant increase in the rate of drainage on both sides. Chylothorax was confirmed by elevated triglyceride level (190 mg/dl) and the presence of chylomicrons in the fluid. Despite total parenteral nutrition (TPN), the daily output of the right chylous effusion was still >1100 ml/day and the left side was >500 ml/day. At 15<sup>th</sup> post-operative day, chemical pleurodesis was instilled by using 60 ml of sterile saline solutions mixed with 20 ml of 10% povidone iodine injected through the right then the left chest tube in 2 consecutive days. The tubes were connected to negative 20 cm H<sub>2</sub>O suction after 2 h of clamping. At 24 h later, a noticeable decrease of chylous pleural effusion was noted and 3 days after, the drainage was serous and <100 ml/day from both sides and we were able to remove the chest tubes and discharge the patient from the hospital after chest X-ray (CXR) which revealed a good expansion of the lung [Figure 2].

After 5 months, at a regular post-operative follow-up visit in the outpatient clinic, the CXR revealed a mild to moderate pleural effusion which re-accumulated on the left side. The pleural effusion was drained with a pigtail thoracocentesis catheter. Pleural fluid was chylous in nature confirmed by the presence of chylomicrons in the fluid with no evidence of any infection. Repeated pleurodesis was attempted using 60 ml of sterile saline solutions and 20 ml of 10% povidone iodine injected through the pigtail which was clamped for 2 h and then reconnected to 20 cm H<sub>2</sub>O negative suction. At 24 h after this procedure, the chylous pleural output stopped definitively and the chest tube was removed after 72 h. Sirolimus 1 mg/day was added for treatment. She was discharged home with target sirolimus level between 6 and 8 ng/ml. We observed no recurrence of the chylous effusion [Figure 3] within 24 months of follow-up after second pleurodesis with stable pulmonary function tests, FEV1 2.3 l (73.5% of predicted).

## Discussion

LAM is a rare, destructive lung disease characterized by an abnormal proliferation of smooth muscle-like cells (LAM cells) in the lung and along the axial lymphatics, which leads to progressive, diffuse cystic changes in the lung parenchyma, obstruction of the airways and lymphatics and loss of pulmonary function.<sup>[4]</sup> Chylothorax is a well-known complication after single or bilateral LT for LAM.<sup>[3]</sup> In general, post-operative chylothorax causes nutritional deficiencies, respiratory dysfunction and dehydration. It also affects immunosuppression, thus increasing vulnerability for infections and may result in a fatal outcome. Thus, the condition requires prompt action by the lung transplant team.<sup>[4]</sup> Chylothorax in LAM can be refractory and difficult to manage. There are multiple options of care but the gold standard for chylothorax treatment still needs to be defined. Conservative management in the form of low-fat diet

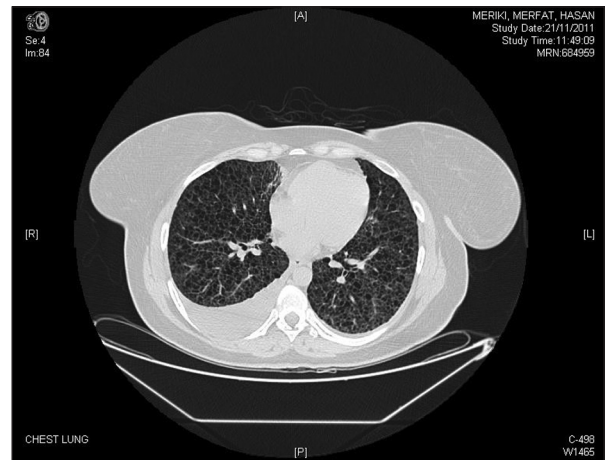


Figure 1: High resolution computed tomographic scan before lung transplantation

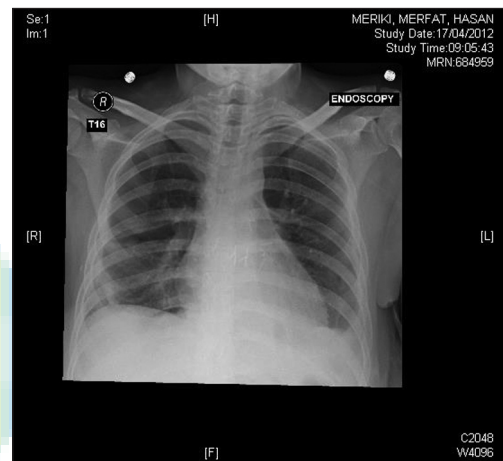


Figure 2: Chest X-ray after the removal of chest tubes post-pleurodesis

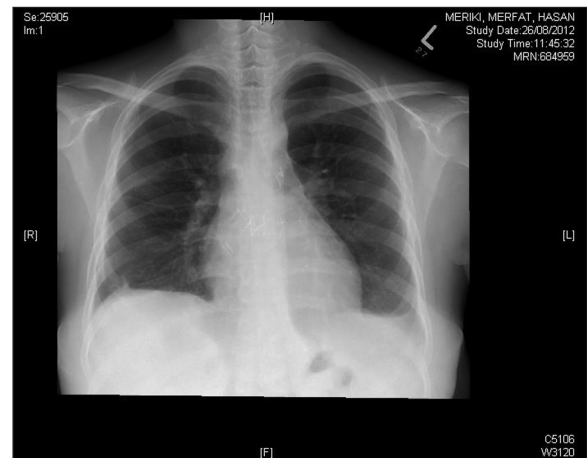


Figure 3: Chest X-ray 24 months post-re-pleurodesis and sirolimus treatment

or TPN should be tried as a first option, but they are frequently unsuccessful. In case of failure of conservative management, repeated tapping or chest tube drainage may suffice in some patients with chylothorax.<sup>[5]</sup> More aggressive surgical methods such as the thoracic duct ligation with or without mechanical pleurodesis or pleurectomy have been successfully used.<sup>[1]</sup>

Among 34 lung transplant recipients with LAM, Boehler *et al.*<sup>[6]</sup> in their study have reported 3 cases of post-operative chylothorax. Chylous effusion resolved in all cases after thoracic duct ligation along with medium-chain triglyceride dietary regimen. In another series by Pechet *et al.*,<sup>[7]</sup> post-operative chylous fistula was observed in 4 of 12 patients who underwent LT for LAM. Favorable results were obtained in all cases after thoracic duct ligation or pleurodesis.

Refractory chylothorax has been effectively controlled in some cases with somatostatin administration, pleuro-peritoneal shunt and chemical pleurodesis with sclerosing agents (nitrogen mustard, tetracycline and talc).<sup>[5]</sup> Povidone iodine pleurodesis was described and used with a high rate (64-96%) of success for malignant pleural effusions. Adverse effects related to povidone use in the pleural cavity are generally dose-related and include chest pain, systemic hypotension, hypothyroidism and visual loss.<sup>[8]</sup> Like other chemical pleurodesis agents the exact mechanism of action of povidone iodine is unclear; however, its lower pH (2.97) or the oxidative and cytotoxic properties of iodine may induce inflammation of the pleural surfaces with subsequent fibrosis.<sup>[8]</sup>

Until date, few reports are available in the literature regarding the use of povidone iodine injection for the management of refractory chylothorax. In this case, the authors were unable to control the chylous pleural effusion by using duct ligation and medical therapies. The injection of povidone in the pleural space was finally effective in stopping the chylous effusion on one side while on the other side, we had to repeat the povidone pleurodesis with the addition of sirolimus to control the chylous effusion. Despite treatment with conventional therapies and bilateral povidone pleurodesis which controlled the chylous effusion completely on the right side and partially for 5 months on the left side, our patient re-accumulated left sided chylous effusion after 5 months after her discharge from the hospital. We decided to redo the povidone pleurodesis on the left side and to add sirolimus, a specific S6 kinase 1 inhibitor that blocks growth factor-driven cell proliferation and abolishes LAM cell abnormal proliferation *in vitro*. Thus, Sirolimus was introduced as a therapy for lung transplant recipients with LAM. Because sirolimus, a mammalian target of rapamycin inhibitor, can correct cellular abnormalities produced by loss of function of tumor suppressor gene tuberous sclerosis (TSC) 1 and TSC2, it could prevent LAM development and chylous production.<sup>[2,9]</sup>

This management prevented the recurrence of chylothorax for 24 months [Figure 3]. A role for sirolimus in routine post-lung transplant immunosuppression for LAM or for recurrent LAM after lung transplant has also been suggested. However, using sirolimus for patients waiting for LT or for patients in the early post-transplant period is not recommended due to its potential risk of bronchial anastomotic dehiscence.<sup>[2]</sup> In refractory or recurrent chylothorax post-LT for LAM, prior to considering more invasive measures such as repeat thoracotomy, pleurodesis with povidone iodine and sirolimus may be considered as a therapeutic option.

## References

1. Rizzardi G, Loy M, Marulli G, Rea F. Persistent chylothorax in lymphangioleiomyomatosis treated by intrapleural instillation of povidone. *Eur J Cardiothorac Surg* 2008;34:214-5.
2. Ohara T, Oto T, Miyoshi K, Tao H, Yamane M, Toyooka S, *et al.* Sirolimus ameliorated post lung transplant chylothorax in lymphangioleiomyomatosis. *Ann Thorac Surg* 2008;86:e7-8.
3. Dauriat G, Brugière O, Mal H, Camuset J, Castier Y, Lesèche G, *et al.* Refractory chylothorax after lung transplantation for lymphangioleiomyomatosis successfully cured with instillation of povidone. *J Thorac Cardiovasc Surg* 2003;126:875-7.
4. Shigemura N, Kawamura T, Minami M, Sawabata N, Inoue M, Utsumi T, *et al.* Successful factor XIII administration for persistent chylothorax after lung transplantation for lymphangioleiomyomatosis. *Ann Thorac Surg* 2009;88:1003-6.
5. Ryu JH, Doerr CH, Fisher SD, Olson EJ, Sahn SA. Chylothorax in lymphangioleiomyomatosis. *Chest* 2003;123:623-7.
6. Boehler A, Speich R, Russi EW, Weder W. Lung transplantation for lymphangioleiomyomatosis. *N Engl J Med* 1996;335:1275-80.
7. Pechet TT, Singhal AK, Meyers BF, Guthrie TJ, Battafarano RJ, Trulock EP, *et al.* Lung transplantation for lymphangioleiomyomatosis. *J Heart Lung Transplant* 2001;20:174.
8. Kelly-Garcia J, Roman-Berumen JF, Ibarra-Perez C. Iodopovidone and bleomycin pleurodesis for effusions due to malignant epithelial neoplasms. *Arch Med Res* 1997;28:583-5.
9. Chen F, Omasa M, Kondo N, Fujinaga T, Shoji T, Sakai H, *et al.* Sirolimus treatment for recurrent lymphangioleiomyomatosis after lung transplantation. *Ann Thorac Surg* 2009;87:e6-7.

**How to cite this article:** Hussein M, Aljehani YM, Nizami I, Saleh W. Successful management of bilateral refractory chylothorax after double lung transplantation for lymphangioleiomyomatosis. *Ann Thorac Med* 2014;9:124-6.

**Source of Support:** Nil, **Conflict of Interest:** None declared.