

Evaluation of Nasogastric Tube Insertion with or without Guide Wire during Laparoscopic Cholecystectomy in Imam Reza AJA Hospital

Mohamadreza Rafiei,¹ Mostafa Shahrezaei,² Mohamad Afsahi,³ Vahid Ziaei,⁴ Saeedreza Ghadirpour,⁵ Ebrahim Hazrati³

¹Associate Professor of Anesthesiology Department of AJA University of Medical Sciences, Imam Reza Hospital, Tehran, Iran

²Associate Professor of Orthopedic Department of AJA University of Medical Sciences, Imam Reza Hospital, Tehran, Iran

³Assistant Professor of Anesthesiology Department of AJA University of Medical Sciences, Imam Reza Hospital, Tehran, Iran

⁴Assistant Professor of Anesthesiology Department of Najaf Abad Azad University of Medical Science

⁵General Physician

ABSTRACT

Purpose: According to frequent needs to gastric decompression by nasogastric tube insertion during laparoscopic Cholecystectomy, the current comparative study was accomplished through single blind clinical trial considering both the presence and the absence of guide wire insertion.

Materials and Methods: Twenty patients were selected for elective surgery of laparoscopic Cholecystectomy with general anesthesia. Guide wires were used in the nasogastric tube insertion operation of patients with even numbers while the operation of patients with odd numbers was not assisted with these guide wires. Afterwards, the considered parameters between the two groups were evaluated. The gathered data was analyzed by SPSS software version 18. The results were considered statistically significant for ($P = .05$).

Results: The two groups were uniform regarding demographic parameters such as age, and sex ($P = .05$). In the group utilized guide wires the surgeon's satisfaction rate was higher while some other parameters such as trial score, bleeding episodes, insertion time, and Rate-Pressure Production Index were meaningfully lower than the those of the group not utilized guide wires. Also, in both groups the success rate of insertion through left nostril was statistically higher ($P = .05$).

Conclusion: In laparoscopic Cholecystectomy, the insertion method of nasogastric tube with guide wires is better than not using the guide wires.

Keywords: laparoscopy; cholecystectomy; ngtube; guide wire; evaluation.

AMHSR 2016;14:41-45
www.journals.ajau.ac.ir

INTRODUCTION

In laparoscopic cholecystectomy, in order to improve the surgeon's field of action specially while the patient is unconscious and unable to cooperate with the anesthesiologist to insert any nasogastric (NG) tube for gastric decompression, this is the anesthesiologist's task to perform these actions with the least repetition and minimal trauma to the patient's airway. NG tube insertion in conscious patients is done by the help of the patient

and through frequent swallowing, but during anesthesia, when patients show no cooperation, this insertion is so difficult that the failure rate on the first try is close to 50%.^(1,2) (Figure 1) After each unsuccessful attempt to insert NG tube, the risk of hemodynamic complications and mucosal bleeding increases.⁽³⁻⁵⁾

Nasogastric tube is used to feed the patients and as a method of treatment to reduce gastric distention (decompress), and therefore to facilitate surgical

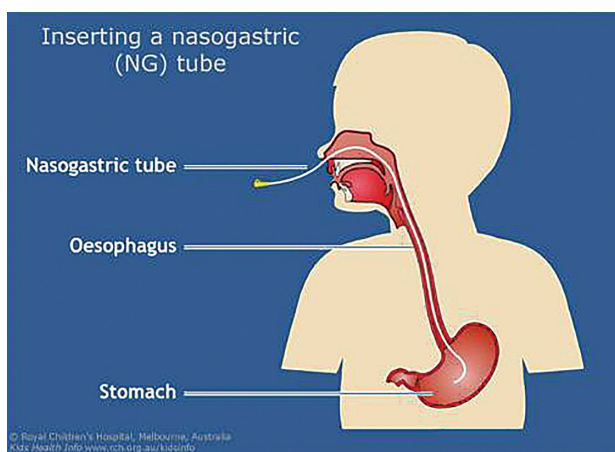


Figure 1. Correct position of the NG-tube

operation.^(6,7) Reid and Smith's study reported that in endoscopic examination 68% of people with open nostrils and no history of nasal obstruction suffer from nasal abnormalities.⁽⁸⁾

Many complications may occur during NG tube insertion including bleeding, tube entering into the brain, pneumothorax, and esophageal perforation.⁽⁹⁻¹²⁾ The golden standard method to ensure a correct insertion of NG tube is doing an X-Ray and determining the tube tip under T12, however, it is clear that this method is not suitable for routine and frequent NG tube applications. Due to the interference with bowel and chest sounds and wrong interpretation of the location of the tube, placing a stethoscope on the stomach for whoosh test is not a reliable method, but aspiration of gastric fluid with a syringe and testing the acidity can be a reliable test.^(13,14)

Awake and conscious patients can cooperate in inserting NG tube by frequent swallowing, but in unconscious patients it is difficult and the failure of the first attempt will be as close as 50%, which can be due to the softening of the tube caused by body temperature, this can also happen when the NG tube tip caught.^{15,16} Blowing gas into the patient's abdomen causes an increase in intra-abdominal pressure, which leads to an increase in the risk of aspiration of gastric contents during the laparoscopic cholecystectomy, on the other hand in order to facilitate the surgery and to enhance the surgeon's field of view it is better to decompress the stomach.⁽¹⁷⁾

Longer transit time can cause more nose bleeding.⁽⁴⁾ Therefore, we decided to present a new method for NG tube insertion in anesthetized and unconscious patient during surgery.

MATERIALS AND METHODS

After Obtaining the approval of University Ethics

Committee (IR.AJAUMS.REC.1394.17) and the informed written consent, this single blind randomized clinical trial was conducted on ASA – I patients with 20 to 60 years of age who admitted to AJA Emam Reza hospital operating room.

Inclusion Criteria

All ASA – I patients, 20 to 60 years of age, who have been admitted to AJA Emam Reza hospital in Tehran for laparoscopic cholecystectomy with general anesthesia.

Exclusion Criteria

Patients who are over 60 years old, people who are ASA Class II, III, and IV, those with nasal polyps or congenital nasal diseases, and people with a history of nose surgery were excluded from the trial.

Patients were selected through Convenience Sampling concurrent with their admission to operation room and were divided into two groups of 20 patients, distinguished based on odd and even numbers, with simple random sampling. The same anesthesia induction procedure was used (all patients received the same method for general anesthesia which is 5 cc/kg fluid preload (Ringer), then being injected with 2.5 µg/kg fentanyl IV and atracurium 0.6 mg/kg and 5 mg/kg sodium thiopental), and for both groups N₂O in 50% oxygen mixture along with a propofol infusion at a dose of 150 µg/kg/min and 0.1 mg/kg of morphine were used for anesthesia. Insertion of a nasogastric tube was done with the help of guide wire for one group while for the other it was not used (the groups were distinguished based on odd and even numbers of each patient). Patients in both groups were divided into two subgroups (again, the two subgroups were distinguished based on odd and even numbers of each patient in each group) to evaluate the insertion from right and left nostril. After NG tube insertion, heart rates are multiplied by systolic blood pressure values to determine the Rate-Pressure Production Index (R.P.P.I). Also, the number of trials for NG tube insertion, the mean time of insertion, and the surgeon satisfaction were recorded for both groups. Obtained information was analyzed statistically by an expert who had no information about patients distribution (single blind RCT).

The informed consent was obtained from the patient and in case he/she was not conscious it was his/her first-degree relative who signed the consent.

Collected data was analyzed by SPSS software for windows (version 20-SPSS).

The comparison of quantitative variables such as age and Rate-Production Index was done using T-Student

testwhile the comparison of qualitative variable such as frequency of nose bleeding, surgeon satisfaction and average time of nasogastric tube insertion was done using Chi-square test. Factorial analysis of variance (between variables or two-sided) was used to determine the rate of successful insertion through left or right nostril in both methods and both sexes.

RESULTS

Demographic characteristics of the patients are presented in **Table 1**. The two groups were not significantly different in terms of baseline characteristics; sex ($P = .343$) and age ($P = .452$).

The surgeon satisfaction in the group with guide wire (casegroup) was higher in comparison with that of the group without guide wire (controlgroup), the number of cases with surgeon satisfaction for the groups were 18 and 13, respectively ($P < .001$). The comparison of values for other variables between the guide wire (case) group and no guide wire (control) group is as follow: Rate-Pressure Production Index (RPPI) with values of 9834.5 ± 1262.57 and 11734.45 ± 1743.12 , respectively ($P < .001$), trial score repetition with values of 17 and 3 for one time and values of 3 and 17 for two and more repetitions, respectively ($p < .001$), insertion time with values of 17 and 12 for the time settings less than 5 minutes and values of 3 and 8 for the time settings more than 5 minutes, respectively ($P = .077$), and bleeding episode with values of 3 and 7, respectively ($P = .144$). (**Table 2**)

This study showed that the rate of successful NG tube insertion was higher through the left nostril than the right one ($P > .001$). (**Table 2**)

Table 3. the distribution of success variable for NG tube insertion according to effective parameters

Groups	Variables		
	Gender	Nostril	
		Left	Right
With guide wire	Male	6	2
	Female	8	4
Without guide wire	Male	6	3
	Female	7	4
P value	.142		
Test	Factorial variance analytic		

The study also found that the gender of patients and the selected nostril make no significant difference in the success rate of tube insertion with or without guide wire ($P = .142$) (**Table 3**)

DISCUSSION

This research studied the NG tube insertion to decompress the stomach during laparoscopic cholecystectomy with and without guide wire and considered the affecting factors. The statistical results showed that there were no significant differences in demographic variables and the two groups had a normal distribution. (**Tables 1**)

In the current study it was found that the surgeon satisfaction was greater in wire guide group ($P = .001$). However, Appukutty and colleagues found that cooling the NG tube and using special wire can facilitate the NG tube insertion.² We showed that both groups have higher rates of successful in NG tube insertion through the left nostril than the right one ($P = .001$)

The results of our study confirmed the AijiBokuand

Table 1. Comparison of demographic factors between the two study groups

Groups	Age				Sex	
	Number	Mean	Standard Deviation	Standard Error	Female	Male
With guide wire	20	42.750	6.9953	1.5642	12	8
Without guide wire	20	44.450	6.6211	1.4805	11	9
P value	0.452				0.343	
Test	Independent sample T-test				Chi-square	

Table 2. The distribution of studied variables in the two groups

Groups	Variables								
	Bleeding	Nostril		Surgeon Satisfaction	Time settings		R.P.P.I* (mean ± SD)	Trial Score Repitition	
		Left	Right		Less Than 5 min	More Than 5 min		Once	Two times or more
With guide wire	3	14	6	18	17	3	9834.5 ± 1262.57	17	3
Without guide wire	7	13	7	13	12	8	8	3	17
P value	.144	<.001		<.001	.077		<.001	<.001	
Test									

*Rate-Pressure Production Index

colleagues' study.¹⁸ Based on the anatomy of the airways and the fact that the right bronchus and trachea are located along with each other, a facilitated insertion of tube into the trachea is expected. However, unlike the tracheal tube insertion, the insertion of nasogastric tube from the left nostril is associated with a greater success rate.¹⁸

It was found that there is a significant difference in term of Rate-Pressure Production Index (RPPI) between the two groups ($P = .001$). This result is explained by the use of guide wire and avoiding the accumulation of nasogastric tube in the mouth leading to the use of less magill forceps, which means less oral mucosa irritation resulting in lower heart rate and blood pressure.⁽¹⁸⁾

The two groups were significantly different in term of trial score for NG tube insertion ($P = .001$). Similar to the results of Appukutty and colleagues' study, this can be done by cooling the tube and preventing its sprain by the means of wire.⁽²⁾

This study found that despite the decline in the time of NG tube insertion through the wire guide method, the two groups had no significant difference in this regard ($P = .077$).

Com TR and colleagues' study also found that the duration of tracheal intubation through the right nostril is lower due to a better guidance towards the trachea, this result can be extended to a better NG tube insertion through the left nostril by "reductio ad absurdum".⁽¹⁹⁾ In this study it was showed that there is less bleeding in guide wire group although there was no statistical significant difference between the two groups ($P = .142$). Based on the fact mentioned in AjiBoku and colleagues' study, this is resulted from less traumatized Kiesselbach plexus vascular network located in the anterior part of the mucosal lining of the nose.⁽¹⁸⁾ The study also found that the gender of patients and the selected nostril make no significant different in the rate of successful insertion with or without guide wire ($P = .142$). However, the obtained statistical results suggest that if the number of samples and participants increases, the relationship can be more significant.

CONCLUSIONS

Whit this clinical trial study we show that in laparoscopic cholecystectomy insertion of NG-tube can be done by using the guide wire while side effects such as nasal bleeding decline.

Also the left nostril is better and preferred for this purpose.

CONFLICT OF INTEREST

None declared.

REFERENCES

- Pillai JB, Vegas A, Brister S. Thoracic complications of nasogastric tube: Review of safe practice. *Interact Cardiovasc Thorac Surg*. 2005;4:429-33.
- Appukutty J, Shroff PP. Nasogastric tube insertion using different techniques in anesthetized patients: A Prospective, randomized study. *Anesth Analg*. 2009;109:832-5.
- Chun DH, Kim NY, Shin YS, Kim SH. A randomized, clinical trial of frozen versus standard nasogastric tube placement. *World J Surg*. 2009;33:1789-92.
- Sim WS, Chung IS, Chin JU, et al. Risk factors for epistaxis during nasotracheal intubation. *Anaesth Intensive Care*. 2002;30:449-52.
- Dwolatzky T, Berezovski S, Friedmann R, et al; A prospective comparison of the use of nasogastric and percutaneous endoscopic gastrostomy tubes for long-term enteral feeding in older people. *Clin Nutr*. 2001;20:535-40.
- Van Eetvelde E, Verfaillie L, Van De Winkel N, Hubloue I. Acute gastric dilatation causing acute limb ischemia in an anorexia nervosa patient. *J Emerg Med*. 2014;46:e141-3.
- Hung CW, Lee WH. A novel method to assist nasogastric tube insertion. *Emerg Med J*. 2008;25:23-5.
- Smith JE, Reid AP. Asymptomatic intranasal abnormalities influencing the choice of nostril for nasotracheal intubation. *Br J Anaesth*. 1999;83:882-6.
- Kuo YC, Wu CS. Spontaneous intramural perforation of the esophagus: case report and review of the literature. *Endoscopy*. 1989;21:153-4.
- Granier I, Leone M, Garcia E, Geissler A, Durand-Gasselien J. [Nasogastric tube: intratracheal malposition and entrapment in a bronchial suture]. *Ann Fr Anesth Reanim*. 1998;17:1232-4.
- Kolbitsch C, Pomaroli A, Lorenz I, Gassner M, Luger TJ. Pneumothorax following nasogastric feeding tube insertion in a tracheostomized patient after bilateral lung transplantation. *Intensive Care Med*. 1997;23:440-442.
- Ferreras J, Junquera LM, Garcia-Consuegra L. Intracranial placement of a nasogastric tube after severe craniofacial trauma. *Oral Surg Oral Med Oral Pathol Oral Radiol Endod*. 2000;90:564-6.
- Society of Pediatric Nurses (SPN) Clinical Practice Committee; SPN Research Committee, Longo MA. Best evidence: nasogastric tube placement verification. *J Pediatr Nurs*. 2011;26:373-6.
- Munera-Seeley V, Ochoa JB, Brown N, et al. Use of a colorimetric carbon dioxide sensor for nasoenteric feeding tube placement in critical care patients compared with clinical methods and radiography. *Nutr Clin Pract*. 2008;23:318-21.
- Best C. Nasogastric feeding in the community: safe and effective practice. *Br J Community Nurs*. 2013;Suppl Nutrition:S8-12.
- Boyes RJ, Kruse JA. Nasogastric and nasoenteric intubation. *Crit Care Clin*. 1992;8:865-78.
- Doyle MT, Twomey CF, Owens TM, McShane AJ. Gastroesophageal reflux and tracheal contamination

during laparoscopic cholecystectomy and diagnostic gynecological laparoscopy. *Anesth Analg* 1998;86:624-8.

18. Boku A, Hanamoto H, Hirose Y, et al. Which nostril should be used for nasotracheal intubation: the right or left? A randomized clinical trial. *J Clin Anesth*. 2014;26:390-4.
19. Coe TR, Human M. The peri-operative complications of nasal intubation: a comparison of nostril side. *Anaesthesia*. 2001;56:447-50.

Corresponding Author:

Ebrahim Hazrati

Address: Anesthesiology Department of AJA University of Medical Sciences, Imam Reza Hospital,

Tel: +98 9123810956

E-mail: dr.hazrati.e@gmail.com

Received: February 2016

Accepted: March 2016

Archive of SID