

## Aneurysmal Bone Cyst of Ischiopubic Ramus: A Rare Location with Literature Review

Rehana Shaikh<sup>1</sup>, Saba Sohail<sup>2</sup>, Badaruddin Sahito<sup>3</sup>, Syeda Erage Safi<sup>4</sup>, Sabiha Zaheer<sup>5</sup>

### Abstract

Aneurysmal bone cyst (ABC) is a locally destructive lesion of the bone rather than a true neoplasm. The pelvis is not an unusual site for an ABC; approximately 12% of cases occur in this location. We present a case of aneurysmal bone cyst (ABC) in ischiopubic ramus in a 22 years old male who presented with right inguinal swelling and pain. He was evaluated with X-ray and Magnetic Resonance Imaging (MRI) of pelvis. A review of literature regarding this rare site of ABC with radiological features is also described in this case report.

ABC of ischiopubic ramus is an uncommon entity hence diagnosis of such a case requires proper clinical, radiological and histopathological evaluation to rule out other differential diagnoses of an expansile, osteolytic lesion. This will help in selecting a proper treatment plan.

**Keywords:** Aneurysmal bone cyst, pelvi, diagnostic imaging, MRI scan, X-ray.

(ASH & KMDC 22(2):124;2017).

### Introduction

Aneurysmal bone cyst (ABC) is a benign, expansile, multiloculated, fluid-filled, cystic, locally destructive, osteolytic lesion of the bone of unknown aetiology which usually occurs in the metaphysis of the long bone<sup>1</sup>. Occurrence of ABC in the flatbone is relatively rare<sup>2</sup>, and 50% of flat bone ABCs are found in the pelvis<sup>3</sup>. It most commonly occurs in first two decades of life and mostly presents with pain and swelling, and sometimes with pathological fracture.

Radiological evaluation of all bone lesions begins with the plain radiograph. The next step in the imaging evaluation includes Computed Tomography (CT) scan, Magnetic Resonance Imaging (MRI) and

<sup>1,2,4,5</sup> Department of Radiology,

Dow Medical College/Civil Hospital Karachi, DUHS.

<sup>3</sup> Department of Orthopaedic Surgery,

Dow Medical College/Civil Hospital Karachi, DUHS

**Correspondence:** Dr. Rehana Shaikh

Department of Radiology,

Dow Medical College/Civil Hospital Karachi, DUHS

Email: rehanawazir@hotmail.com

Date of Submission: 20<sup>th</sup> April 2017

Date of Acceptance: 30<sup>th</sup> May 2017

skeletal scintigraphy which depends on the lesion's radiological appearance and its location. These are commonly treated with curettage and bone grafting<sup>4</sup>. Recurrence rate in pelvic ABC after surgical treatment is reported around 14%<sup>4</sup>. We present a case of aneurysmal bone cyst (ABC) in ischiopubic ramus in a young male. Additionally, we discuss the radiological features and review the literature. This case highlights the importance of ABC in the radiological differential diagnosis of multiloculated lytic lesion even in locations other than the long bones, which is the purpose of reporting this case.

### Case Report

A 22 year old male was referred to the radiology department for X-ray pelvis. He gave a history of right inguinal swelling for 1 year after a fall. He developed dull pain with gradual increase in the size of the swelling. The pain was localised to the inguinal region with no radiation. There was no history of concomitant fever or weight loss. The patient was not complaining of any urinary symptoms or change in his bowel habits. The past medical and surgical

histories were unremarkable. Family history was insignificant. Routine laboratory tests were within normal limits. General physical and systemic reviews were unremarkable. Local examination of swelling showed a non-tender bony hard swelling, fixed to the bone in right inguinal region. The overlying skin was normal. The right femoral pulse was normal. The movement of the hip was free. Power and sensation of the right lower limb were normal. Then, the X-ray and MRI of the pelvis were performed. The X-ray showed an expansile, multiloculated, blowout lytic lesion with cortical thinning in the right ischio-pubic ramus. No pathological fracture was found (Fig. 1). On MRI, it appeared as a well-defined expansile lesion with fluid-fluid levels in right ischio-pubic ramus including ischial spine, showing heterogeneously hyperintense signals on T2-weighted (T2W) and short tau inversion recovery (STIR) imaging, isointense with hyperintense foci on T1-weighted (T1W) imaging, and peripheral and septal enhancement on post-Gd images. It was not associated with soft tissue component. No evidence of vascular or neural involvement. Hip joint was unremarkable (Figure 2a-d).

The differential diagnosis of ABC, included giant cell tumour chondroblastoma or telangiectatic osteosarcoma, but on the basis of age, clinical history and radiological findings the provisional diagnosis of aneurysmal bone cyst (ABC) was made. Then biopsy of the lesion was taken. The histopathology revealed predominantly chondromyxoid areas, few of these showing cystic spaces lined by giant cells. The stromal cells were uniform having spindle to ovoid nuclei. Areas of haemorrhage were also seen (Figure 3). This confirmed the ABC. Then, the patient underwent surgery with curettage and allografting of bone and recovered uneventfully in post-operative period. Patient is currently on follow up. We will follow this patient till 1 year to assess the recurrence.

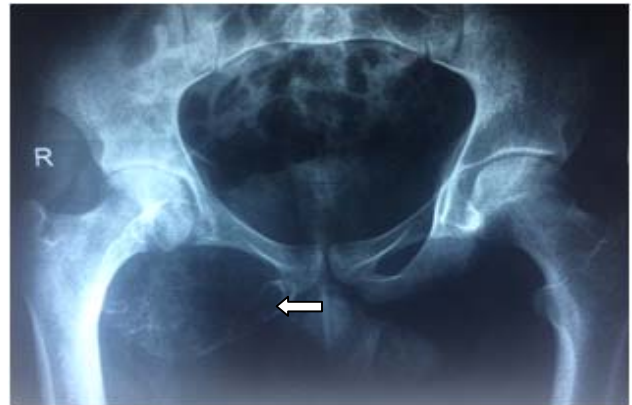

Fig 1. X-ray pelvis including both hip joints shows an expansile, multiloculated, lytic lesion with cortical thinning in the right ischio-pubic ramus (arrow).

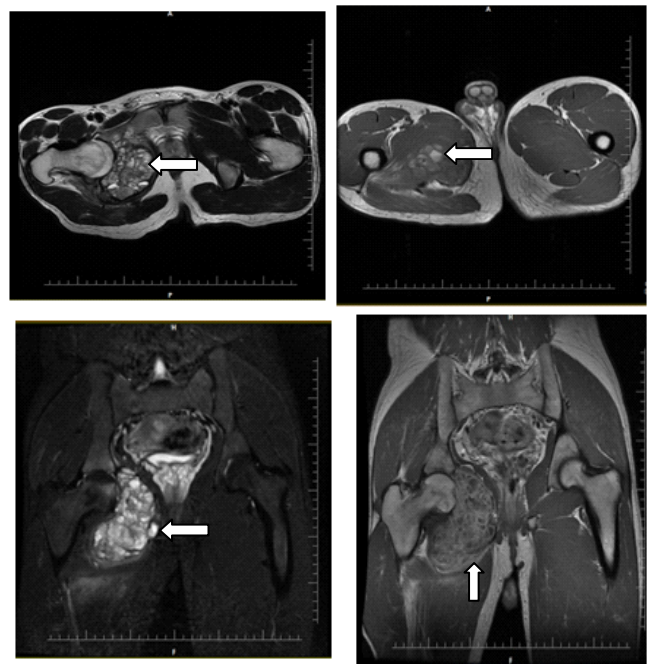


Fig 2. (a-d). Axial T2 and T1, and coronal STIR and post-Gd images show a well-defined, expansile lesion with fluid-fluid levels (left arrow) in the right ischio-pubic ramus showing peripheral and septal enhancement (up arrow) on post Gd image.

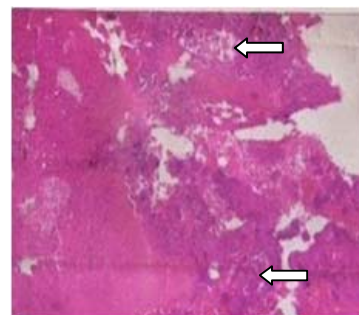


Fig 3. Histological picture of ABC showing giant cells (arrows)

## Discussion

ABC is a benign, relatively aggressive lesion of bone. It was first described in 1942 by Jaffe and Lichtenstein<sup>5</sup>. The origin of ABCs is not well understood still, but many hypotheses have been proposed, and until very recently, the most commonly accepted idea is that an aneurysmal bone cyst is due to the local haemodynamic disturbances with an increased venous pressure and a resultant dilation and rupture of the local vascular network<sup>6</sup>. It represents almost 1% of primary bone lesions<sup>2,7</sup>. It is commonly seen in the metaphysis of long bones with predilection to the distal femur, proximal humerus, proximal tibia etc. It may be seen in flat bones, such as pelvis or scapula, as well as in the vertebrae. The pelvis is not an unusual site for an ABC; approximately 12% of cases occur in this location<sup>2,7</sup>. But, the pubic ramus is a rare site for ABC<sup>1</sup>, which is the reason for reporting this case. The exact numbers of reported cases are not mentioned in the literature. ABCs are primary lesions without any precursor osseous lesion in 70% of cases and in 30% arise as a secondary lesion from a preexisting osseous lesion like an eosinophilic granuloma, a simple bone cyst, a chondroblastoma, a giant-cell tumour (GCT), or an osteosarcoma<sup>7,8</sup>.

ABC is most common in patients less than 20 years of age but can be seen in older patients, like our patient is 22 year old. These lesions are slightly more common in females than males. Lesions are typically expansile, eccentric and lytic, with thinning of overlying cortex. A sclerotic rim and internal trabeculation may be present<sup>4,9</sup>. Magnetic resonance imaging may show a well-defined, multiloculated lesion with fluid-fluid levels and contrast enhancing internal septa. High-to-low T1- and T2-weighted signal intensity in the fluid-fluid levels is presumably due to blood products of varying age<sup>4,9</sup>, as seen in the MRI of our patient. CT scan will also reveal an expansile, multiloculated lesion with enhancing septa. It may show fluid-fluid level. But MRI is the superior imaging modality in showing the soft tissues and neurovascular bundle involvement, while the skeletal scintigraphy will show

increased tracer uptake within the lesion. Histopathologically, ABC is characterised by haemorrhagic, cystic and cavernous spaces surrounded by fibrous septa composed of mild to moderately mitotically active spindle cells intermixed with scattered osteoclast-like multinucleated giant cells. Areas of new and reactive bone formation can also be found<sup>3,9</sup>. Various studies show that the recurrence rate in pelvic ABC is about 14% due to multiple factors, like location of lesion, proximity of neurovascular bundle to the lesion and vulnerability of cartilages of the adjacent joints<sup>3</sup>.

There are various treatment modalities based on the site and size of the lesion, which includes curettage, which may be supplemented with various adjuvant therapies such as bone grafting, use of liquid nitrogen, phenol instillation and polymethyl methacrylate (PMMA) cement to reduce the recurrence rate<sup>6,9,10</sup>, depending on the choice of the orthopaedic surgeon. Our patient underwent curettage with allografting of bone. Currently the patient is on follow up.

## Conclusion

ABC of ischiopubic ramus is a rare entity so it is a challenging tumour in making diagnosis and managing the patient. The purpose of this case is to report an uncommon case of ABC in the ischiopubic ramus that was successfully managed with intralesional curettage and allografting of bone.

## Conflict of Interest

Authors have no conflict of interests and no grant/ funding from any organization for this study and consent was taken from the patient prior to reporting this case.

## References

1. Khan AQ, Siddiqui YS, Parameshwar A, Anwar Sherwani MK. Aneurysmal bone cyst of the pubis. A rare presentation. *Saudi Med J* 2010;31:317-20.
2. Bajracharya S, Khanal GP, Sundas A, Pandey SR, Singh MP. Aneurysmal bone cyst of the pelvis: a challenge in treatment: review of the literature [Online]. *Iowa Orthop J* 2007;8:1. Available from:

- <https://print.ispub.com/api/0/ispub-article/6180>. Accessed on May 3, 2017.
3. Hetaimish BM, Alshaya OS. Pediatric aneurysmal bone cyst in the ischial region. *Saudi Med J* 2016;37:799-803. [DOI: 10.15537/smj.2016.7.13945]
  4. Kransdorf MJ, Sweet DE. Aneurysmal bone cyst: concept, controversy, clinical presentation, and imaging. *AJR Am J Roentgenol* 1995;164:573-80. [DOI: 10.2214/ajr.164.3.7863874].
  5. Jaffe HL, Lichtenstein L. Solitary unicameral bone cyst with emphasis on the roentgen picture, the pathologic appearance and the pathogenesis [Online]. *Arch Surg* 1942;44:1004-25. Available from: <http://jamanetwork.com/journals/jama-surgery/article-abstract/545805>. Accessed on May 3, 2017. [DOI: 10.1001/archsurg.1942.01210240043003].
  6. Nayak A, Kulkarni S, Kulkarni A, Natesh K, Bami M. Aneurysmal bone cyst of the pubis: a case report. *J Clin Diagn Res* 2013;7:1740-2. [DOI: 10.7860/JCDR/2013/5514.3254].
  7. Al Sobeai M, Al Juhani W. Pelvic Aneurysmal Bone Cyst: Case Report and Literature Review [Online]. *International Journal of Surgical Cases* 2015;1:20-5. Available from: <http://surgicalcasesjournal.com/pelvic-aneurysmal-bone-cyst-case-report-and-literature-review/>. Accessed on May 3, 2017.
  8. Bonakdarpour A, Levy WM, Aegerter E. Primary and secondary aneurysmal bone cyst: a radiological study of 75 cases. *Radiology* 1978;126:75-83. [DOI: 10.1148/126.1.75].
  9. Rao A, Samant PD, Varshneya A. Aneurysmal Bone Cyst of Pubic Ramus: A Rare Entity. *J Orthop Case Reports* 2013;3:42-5. [DOI: 10.13107/jocr.2250-0685.131].
  10. Nassef AA, Ebeid WA, Ghoneimy A. Primary treatment of aneurysmal bone cyst of the pelvis by transcatheter arterial embolization [Online]. *Med J Cairo Univ* 2013;81:449-55. Available from: <http://erepository.cu.edu.eg/index.php/MJCU/article/view/1261>. Accessed on May 6, 2017.