

*Case report*

## Aspiration of an incisor tooth after adenotonsillectomy in a 10-year-old Saudi boy

A. Alabidi<sup>1</sup>

### Introduction

Endotracheal intubation and some oral cavity procedures in otolaryngology carry the risk of dental trauma if the anaesthetist or surgeon does not handle the procedure carefully or if the preoperative examination of the oral cavity is not done properly. The risk is greatest in children where the teeth at risk might be avulsed and the chance of pulmonary aspiration becomes very high. This will necessitate prompt recognition and early treatment to minimize the potentially serious and fatal consequences. This article is a report of a child who aspirated an incisor tooth following adenotonsillectomy.

### Case report

A 10-year-old healthy Saudi boy was admitted to Aseer Central Hospital, Abha, Saudi Arabia, for an elective adenotonsillectomy. During intubation, the anaesthetist noticed that both maxillary incisors were loose; one came out and was given to the mother and the other one was left in place. The adenotonsillectomy was uneventful. On the first postoperative day, the patient developed cough and chest pain with no distress or fever; his O<sub>2</sub> saturation was 88%–91% on room air with a slight decreased air entry

in the left side of the chest. The child was treated medically and a paediatrician was consulted. On the second postoperative day, there was no improvement, so a chest X-ray was done which showed a whitish shadow, a foreign body in the left main bronchus just above the carina (Figures 1 and 2). Careful examination of the oral cavity revealed that the second maxillary incisor tooth was not found. After explaining to the parents, the decision was taken to do a rigid bronchoscopy under general anaesthesia and the

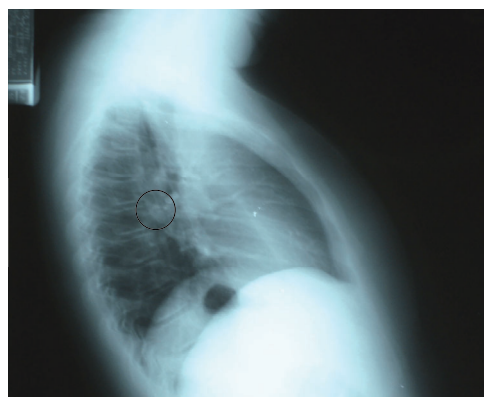

Figure 1 Lateral chest X-ray showing location of tooth (circled)

<sup>1</sup>Department of Surgery, King Khalid University, Abha, Saudi Arabia (Correspondence to A. Alabidi: aalabidi@yahoo.com).

Received: 07/09/05; accepted: 28/11/05

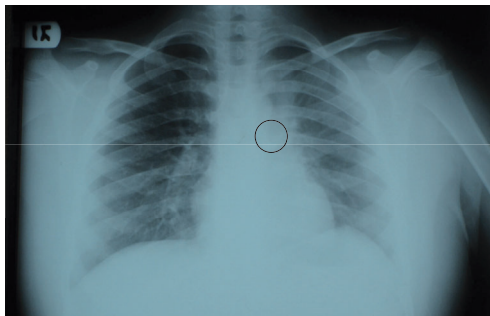


Figure 2 Posterior/anterior chest X-ray showing location of tooth (circled) in the left main bronchus

missing tooth was removed from the left main bronchus. On the third postoperative day, the child's medical condition improved dramatically and he was discharged in a stable condition.

## Discussion

Medicolegally, damage to the teeth is the most common complaint against anaesthetists [1]; 85% of injured teeth are the upper incisors [2]. Dental complications are common in otolaryngology procedures, including adenotonsillectomy, especially in children. A thorough dental history and oral cavity examination before intubation or upper aerodigestive procedures are very important and should be part of the preoperative evaluation in both child and adult patients. A careful check for loose primary teeth and dental pathology, in addition to parental counselling about any possible

dental complications, is necessary before any otolaryngology procedure under general anaesthesia. Only a few cases have been reported in the English literature about tooth aspiration, mostly in dental journals, that were either related to dental procedures [3–7] or to maxillofacial trauma [8,9] or in association with other procedures and conditions [10–12]. In our case, the tooth aspiration was related to adenotonsillectomy. We did not find any report of similar cases in a Medline search, even from the otolaryngology journals.

The recommendations from this case, especially for residents and junior surgeons in otolaryngology can be summarized as follows:

1. Counsel the patient or guardian preoperatively regarding the possibility of dental complications in order to avoid medicolegal complaints.
2. Make a careful preoperative examination of the dental condition.
3. Count the teeth before any oral cavity or endoscopic procedure.
4. During the procedure, use a packing at the hypopharyngeal area and remove it at the end of the procedure.
5. At the end of the procedure, recount the teeth, especially in children, and report any missing teeth.
6. Advise the nurses in the recovery room to clean the mouth carefully to avoid accidental dental trauma.
7. Dental consultation is important in some cases pre- or postoperatively, in managing cases at risk.

## References

1. Owen H, Waddell-Smith I. Dental trauma associated with anesthesia. *Anaesthesia and intensive care*, 2000, 28(2):133–45.
2. Givol N et al. Perianesthetic dental injuries: analysis of incident reports. *Journal of clinical anesthesia*, 2004, 16(3):173–6.

3. Ulku R, Baskan Z, Yavuz I. Open surgical approach for a tooth aspirated during dental extraction: a case report. *Australian dental journal*, 2005, 50(1):49–50.
4. Kurata K, Ohmori I. Inhalation of an avulsed primary tooth. *Oral surgery, oral medicine, and oral pathology*, 1991, 71(1):128–9.
5. Birrer RB, Garren BA. Tooth aspiration in a six-year-old boy. *American journal of emergency medicine*, 2001, 19(7):598–600.
6. Holan G, Ram D. Aspiration of an avulsed primary incisor. A case report. *International journal of paediatric dentistry*, 2000, 10(2):150–2.
7. Tiwana KK, Morton T, Tiwana PS. Aspiration and ingestion in dental practice: a 10-year institutional review. *Journal of the American Dental Association*, 2004, 135(9):1278–91.
8. McIntosh GC, Steadman RK, Gross BD. Aspiration of an unerupted permanent tooth during maxillofacial trauma. *Journal of oral and maxillofacial surgery*, 1982, 40(7):448–50.
9. Delap TG et al. Bilateral pulmonary aspiration of intact teeth following maxillofacial trauma. *Endodontics & dental traumatology*, 1999, 15(4):190–2.
10. Levis AA, Smith RM. Endobronchial aspiration of a tooth: an unusual anesthetic complication. *Anesthesia and analgesia*, 1965, 44:355–7.
11. Kisby L, Tsamtsouris A. Aspiration of a primary tooth by a child with congenital encephalopathy. *Journal of pedodontics*, 1978, 3(1):87–92.
12. Steelman R et al. Aspiration of a primary tooth in a patient with a tracheostomy. *Special care in dentistry*, 1997, 17(3):97–9.

#### Note of appreciation

We would like to draw our readers' attention to the list of reviewers at the end of this issue. The scientific integrity and standard of the information disseminated through EMHJ depends greatly on the critical judgement of our reviewers. We would like to extend our sincere thanks and gratitude to them all for giving voluntarily of their time so willingly.