

Biotinidase deficiency: a treatable genetic disorder in the Saudi population

S. Joshi,¹ M.A. Al-Essa,¹ A. Archibald² and P.T. Ozand^{1,2}

SUMMARY Biotinidase deficiency is an autosomal recessive genetic disorder which is not uncommon in the Saudi population. Biotinidase is responsible for biotin recycling and biotin is an essential cofactor for activation of the carboxylase enzymes. Absence of biotinidase leads to infantile or early childhood encephalopathy, seizure disorder, dermatitis, alopecia, neural deafness and optic atrophy. The disease can be diagnosed by simple fluorometric enzyme assay. Treatment with biotin is both cheap and simple, resulting in rewarding clinical recovery and normalization of the biochemical, neuroradiological and neurophysiological parameters. If neglected, however, a patient may die of acute metabolic acidosis or may suffer from permanent neural deafness and optic atrophy, with mental and motor handicap. We describe the detection and treatment of 20 cases of biotinidase deficiency in our hospital and recommend the introduction of a neonatal screening programme for this disorder.

Introduction

Biotin is a member of the vitamin B complex group. It is mostly derived from the diet and possibly also synthesized by intestinal microflora. The requirement in the paediatric age group is very small (35 µg per day). Biotin is a cofactor for four carboxylases that are important for amino acid catabolism, fatty acid synthesis and gluconeogenesis [1–3]. Biotinidase is an essential enzyme for endogenous biotin recycling [4–6].

Absence or deficiency of biotinidase causes a reduction in free biotin in the body, leading to the disease state known as "late-onset multiple carboxylase deficiency". Therefore, children with biotinidase deficiency become secondarily biotin defi-

cient. If they are left untreated, this results in the development of neurological and cutaneous features [6–8]. The clinical presentation includes lethargy and hyperventilation, vomiting, hypotonia, uncontrolled seizures, global developmental delay, dermatitis, alopecia, and hearing and visual impairment [1,2].

Neonatal screening for biotinidase deficiency is performed in about half of the states in the United States of America and in over 20 countries [9]. The disorder is relatively common in Saudi Arabia and is estimated to be 1 in 125 000 births [10].

We describe the detection and treatment of cases of biotinidase deficiency in our hospital. Our findings highlight the importance of early recognition of this disorder preferably through a neonatal screening

¹Department of Paediatrics; ²Department of Biological and Medical Research, King Faisal Specialist Hospital and Research Centre, Riyadh, Saudi Arabia.

Received: 10/00/98; accepted: 31/10/99

programme, since early treatment with biotin is successful and prevents permanent neurological complications.

Patients and methods

During the period 1992–1996, at the metabolic unit of King Faisal Specialist Hospital and Research Centre, we detected 20 children with biotinidase deficiency. The cases were referred mostly with the diagnosis of uncontrolled infantile myoclonic seizures, hypotonia and developmental delay. Besides taking a complete medical history and carrying out a physical examination, the following investigations were performed: blood gases, lactic and pyruvic acid levels, blood tandem mass spectrometry, urine gas chromatography/mass spectrometry, biotinidase assay, computed tomography scan and/or magnetic resonance imaging of the brain, and electroencephalography. Brain stem auditory evoked response and visual evoked potentials were assessed in all confirmed patients. Patients were treated with biotin (10 mg twice daily) and were followed initially every month and after satisfactory response, every 3 months. Biotinidase assay was conducted on serum specimens, using the fluorometric method of Wastell et al. [11]. Informed written consent of the parents was obtained to use photographs of their children.

Results

There were 14 male and 6 female patients in the study. The age ranged from 22 days to 4 years with a mean of 13 months. A history of consanguinity was found in 12 (60%) of the families. Three families had another affected sibling with the same disease. The clinical findings and laboratory data are summarized in Table 1.

Table 1 Clinical and laboratory results of patients with biotinidase deficiency

Results	No.	%
Clinical presentation (20 patients)		
Uncontrolled seizures	11	55
Hypotonia	13	65
Global developmental delay	14	70
Skin rash	4	20
Alopecia	5	25
Coma	4	20
Neural hearing impairment	4	20
Optic atrophy	4	20
Consanguinity	12	60
Biochemical data (20 patients)		
Attacks of ketolactic acidosis	12	60
Abnormal findings in blood MS/MS and urine GC/MS	10	50
Deficient biotinidase (0%–4% enzyme activity)	20	100
CT/MRI of the brain (13 patients)		
Brain atrophy and white matter disease	11	85
Electroencephalogram (10 patients)		
Generalized slow waves +/- spikes	8	80
Abnormal brain stem auditory evoked potentials (20 patients)	4	20

Blood MS/MS findings: C3 (propionylcarnitine) 3-methylcrotonylcarnitine, and hydroxy C5 carnitine (hydroxyisovaleryl carnitine)

Urine organic acids by GC/MS: 3-hydroxyisovaleric, 3-hydroxypropionic, propionic, methylcitric, and lactic acids, 3-methylcrotonylglycine, propionylglycine and tiglylglycine

MS/MS = tandem mass spectrometry

GC/MS = gas chromatography/mass spectrometry

CT = computed tomography

MRI = magnetic resonance imaging

Follow-up

The initial picture and the dramatic improvement in the facial appearance and hair growth of one patient over 3 to 8 weeks of therapy with biotin are shown in Figures 1a–1c. This was a 3-month-old male infant

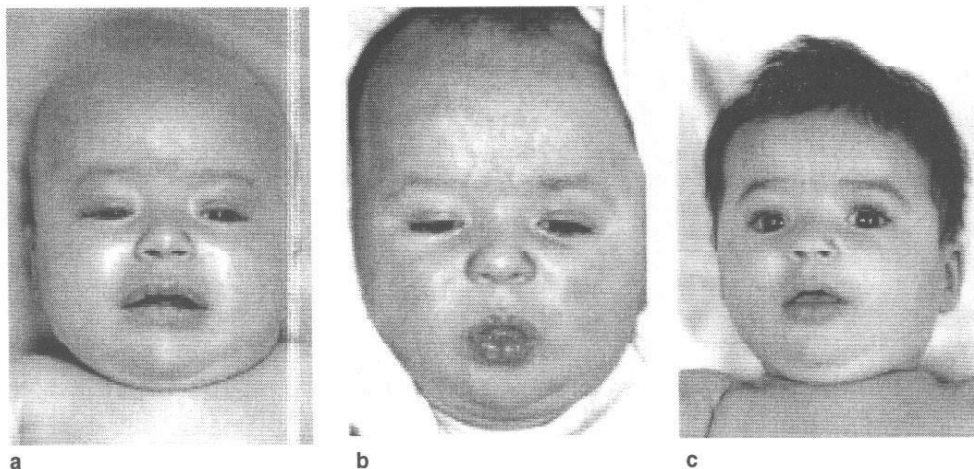


Figure 1 Total alopecia in a 3-month-old male infant who presented with severe myoclonic seizures unresponsive to various anticonvulsant drugs, hypotonia and developmental regression (a). The same patient 3 (b) and 8 weeks (c) after biotin therapy. There is dramatic improvement in the facial appearance and hair growth. The other abnormal clinical manifestations had normalized after biotin treatment.

who presented with severe myoclonic seizures (unresponsive to various anticonvulsant drugs), hypotonia, developmental regression, dermatitis and alopecia. His clinical manifestations reverted to normal after biotin treatment.

In all the patients, seizures were controlled within a few days of biotin therapy and they were gradually weaned off anticonvulsants. Skin rash, hypotonia, poor feeding and activity improved within a few days. Developmental milestones (including cognitive function, and motor, adaptive and social skills) were achieved and alopecia improved within weeks in all but one child who initially presented in a coma. Sensorineural deafness, confirmed both clinically and by auditory and neurophysiological studies, and poor speech were noted in four patients despite adequate treatment. Mild optic atrophy was seen in four patients,

without visual acuity being noticeably affected. Cortical atrophy and white matter disease (Figures 2a and 3a) showed considerable recovery (Figures 2b and 3b). Abnormal electroencephalographic findings completely normalized shortly after biotin therapy.

Discussion

Biotinidase deficiency should be thought of in the differential diagnosis of any infantile or early childhood encephalopathy, especially if associated with seizures. The seizures are characteristically unresponsive to conventional anticonvulsant treatment and are mostly myoclonic in nature. The encephalopathy is probably due to raised lactic acid levels in the brain, secondary to decreased pyruvate carboxylase activity as a

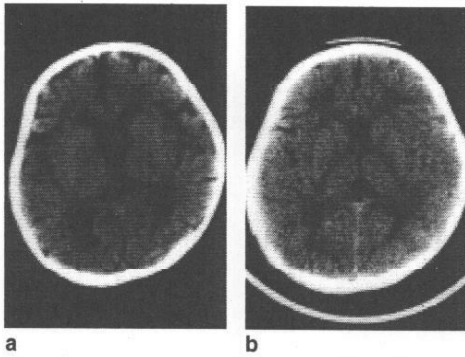


Figure 2 Computed tomography scan of the brain of a biotinidase-deficient patient, (a) before and (b) after treatment with biotin. Note the cerebral atrophy which improved after therapy.

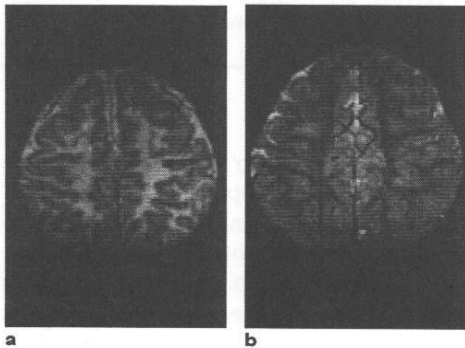


Figure 3 Magnetic resonance image of the brain (T_2 -weighted image) of a biotinidase-deficient patient, (a) before and (b) after treatment with biotin. There was a significant reversal of the white matter disease.

result of biotinidase deficiency. The alopecia, and seborrhoeic and/or atopic dermatitis when present, are highly indicative of the diagnosis and are probably related to fatty acid abnormalities attributable to the deficient activity of acetyl-CoA carboxylase [1].

Laboratory studies often reveal ketolactic acidosis and abnormal urinary organic acids. These findings commonly occur intermittently during acute metabolic crisis. The most frequently observed urine metabolite is β -hydroxyisovaleric acid. Other organic acids are β -methylcrotonylglycine, β -hydroxypropionate and methylcitrate. The disease can be easily diagnosed by a fluorometric or colorimetric enzyme assay in serum.

Treatment with oral biotin (5–10 mg/day) is both cheap and rewarding, especially if started early. The clinical symptoms, neuroradiological and neurophysiological findings, as well as biochemical tests will normalize after biotin therapy. However, if treatment is neglected, the recurrent metabolic crises will result in long-term sensorineural hearing loss and optic atrophy [1,12,13]. This is possibly caused by accumulation of organic acids and/or biocytin or larger biotinyl peptides permanently affecting the developing auditory and optic pathways.

The high consanguinity frequency (60% of the families studied) as well as the presence of more than one affected sibling in the same family confirm the autosomal recessive mode of inheritance of this genetic disorder. At present, only patients suspected clinically of having or being at high-risk of biotinidase deficiency are tested for this disorder. Since the disease is relatively common in Saudi Arabia, and the method used for enzyme testing is both sensitive and specific, a nationwide screening programme of all neonates is recommended. Early treatment with biotin substantially alters the outcome by preventing the lifelong crippling consequences, particularly the permanent hearing loss. Furthermore, public health education about this neurometabolic disease and premarital counselling are recommended.

References

1. Wolf B. Disorders of biotin metabolism. In: Scriver CR et al., eds. *The metabolic and molecular bases of inherited disease*, 7th ed. New York, McGraw-Hill, 1995:3151-80.
2. Wolf B et al. Biotinidase deficiency: the enzymatic defect in late-onset multiple carboxylase deficiency. *Clinica chimica acta*, 1983, 131:273-81.
3. Achuta Murthy PN, Mistry SP. Biotin. *Progress in food and nutrition science*, 1977, 2:405-55.
4. Pispas J. Animal biotinidase. *Annales medicinales experimentales biologiae fennicae*, 1965, 43(suppl. 5):1-39.
5. Wolf B et al. Biotinidase deficiency: the possible role of biotinidase in the processing of dietary protein-bound biotin. *Journal of inherited metabolic disease*, 1984, 7(suppl. 2):121.
6. Wolf B et al. Biotinidase deficiency: a novel vitamin recycling defect. *Journal of inherited metabolic disease*, 1985, 8(suppl. 1):53-8.
7. Wolf B et al. Biotinidase deficiency: initial clinical features and rapid diagnosis. *Annals of neurology*, 1985, 18:614-7.
8. Wolf B. Disorders of biotin metabolism: treatable neurological syndromes. In: Rosenberg R et al., eds. *The molecular and genetic basis of neurological disease*. Stoneham, Massachusetts, Butterworth Publishers, 1993:569-81.
9. Wolf B, Heard GS. Screening for biotinidase deficiency in newborns: worldwide experience. *Pediatrics*, 1990, 85:512-7.
10. Rashed M et al. Experience of King Faisal Specialist Hospital and Research Centre with Saudi organic acid disorders. *Brain and development*, 1994, 16(suppl.):1-6.
11. Wastell H, Dale G, Bartlett K. A sensitive fluorometric rate assay for biotinidase using a new derivative of biotin, biotinyl-6-aminoquinolone. *Analytical biochemistry*, 1984, 140:69.
12. Al-Essa M, Sakati N, Ozand PT. *An atlas of common metabolic and genetic diseases*. Riyadh, Saudi Arabia, King Faisal Specialist Hospital and Research Centre, 1997:114-5.
13. Al-Essa M, Ozand PT. *Manual of metabolic diseases*. Riyadh, Saudi Arabia, King Faisal Specialist Hospital and Research Centre, 1998:30-1.