

Some aspects of the use of oral contraceptives as growth-promoting agents in poultry

Ismail A. Sadek,¹ Hanaa M. Ismail,² Hassan N. Sallam³ and Mohamed Salem⁴

بعض مظاهر استعمال موانع الحمل الفموية لأغراض تسمين الدواجن
إسماعيل أحمد صادق ، و هناء محمد إسماعيل ، وحسن نعمان سلام ، ومحمد سالم

توجد الآن مستحضرات هرمونية وشبه هرمونية عديدة تتميز بقدرة فائقة على زيادة سرعة نمو حيوانات المزارع ، وعلى زيادة الكفاءة الغذائية للأعلاف . ولقد أدى إطعام الدجاج بالجرعات التي يستهلكها بعض مربي الدواجن في مصر ، من موانع الحمل الستيرويدية (أنوفلار) ، إلى تكوّن مخلفات استروجينية كبيرة في عضلات وأكباد الدواجن بالمقارنة بمجموعة من الدواجن الشاهدة . وأسفر فحص أكباد الدجاج المعالج بالأنوفلار بالمجهر الإلكتروني ، عن تغيرات مهمة في مستوى البنية الدقيقة . وتشمل هذه التغيرات كلا من النواة والعضيات الهيولية (السيتوبلازمية) . وتماثل هذه التغيرات ما يحدثه في الدجاج المركب ٧-١٢ ثنائي مثيل بنز (أ) أنتراسين . ويستتج من ذلك أن استعمال موانع الحمل الستيرويدية الفموية كعوامل بناء ينطوي على خطر نوعي في الدجاج نفسه ، وربما في من يأكلون هذا الدجاج .

There are now several hormone and hormone-like agents that can improve the rate of growth and efficiency of feed use of farm animals. Feeding chickens with oral contraceptive steroids at the dose used by some poultry growers in Egypt has led to the formation of high estrogen residues in the muscles and the liver compared with controls. Electron microscopy of the livers of treated chickens revealed changes at the ultrastructural level. These alterations involve both the nucleus and cytoplasmic organelles, and are similar to those induced by 7, 12-dimethylbenz[a]anthracene in chickens. It is concluded that the use of oral contraceptive steroids in chickens as anabolic agent is a specific risk to chickens and probably to the consumer.

Certains aspects de l'utilisation des contraceptifs oraux en tant qu'agents d'accélération de la croissance de la volaille

Il existe aujourd'hui plusieurs hormones et agents de type hormonal qui peuvent améliorer le taux de croissance des animaux d'élevage ainsi que l'efficacité de l'apport alimentaire pour ces animaux. Le fait de nourrir des poulets avec des stéroïdes contraceptifs oraux à la dose utilisée par certains éleveurs de volailles en Egypte a entraîné la formation d'importants résidus d'oestrogènes dans les muscles et le foie par rapport à ceux des poulets témoins. La microscopie électronique du foie des poulets traités a laissé apparaître des changements au niveau de l'ultrastructure. Ces altérations impliquent les organites cellulaires et cytoplasmiques et sont similaires à celles qui sont provoquées par le 7,12-diméthylben[a]anthracène chez les poulets. On parvient à la conclusion selon laquelle l'utilisation de stéroïdes contraceptifs oraux chez les poulets en tant que substances anabolisantes constitue un risque spécifique pour les poulets et probablement pour le consommateur.

¹ Department of Zoology, Faculty of Science; ² Department of Food Analysis, High Institute of Public Health; ³ Department of Obstetrics and Gynaecology, Faculty of Medicine; ⁴ Department of Animal Production, Faculty of Agriculture, Alexandria University, Alexandria, Egypt.

Introduction

The use of compounds exhibiting sex hormone-like activities as anabolic agents was introduced into agricultural practice about 35 years ago. Ever since then, the discussion on the risk to public health of residues of these compounds in food of animal origin has continued. Different positions have developed, and while some countries, like the United States of America, feel that controlled use of certain compounds is safe, other countries strictly prohibit their application and, in particular, the use of "estrogens" [1,2].

Oral contraceptive steroids have been used at excessively high doses as growth-promoting agents by some poultry growers in Egypt. The purpose of this study is to assess the formation of residues in the muscle and liver of chickens of contraceptive steroids applied orally at the same dose used by poultry growers and the resultant level of estrogen in chickens. A further aim was to study changes in the ultrastructure of the liver induced by this treatment

Materials and methods

One hundred chicks of the breed Matrouh Pallet, two weeks of age, were divided at random into four groups of 25 each. The birds were fed broiler diet *ad libitum* and treated as follows:

1. The animals in Group A were given contraceptive pills at the same dose used by poultry growers in Egypt (four strips of Anovlar/100 kg diet) for four weeks. Each strip contains 21 pills and each pill contains 21 milligrams norethisterone acetate + 1.05 milligrams of ethinyl estradiol.
2. The birds in Group B were injected with 7, 12-dimethylbenz[*a*]anthracene (DMBA) at a dose of 1 milligram in 0.1 millilitres olive oil per bird, once a week for four weeks.
3. The experimental birds in Group C received contraceptive pills and DMBA at the same dose levels for the same period.
4. The chickens in Group D were fed the basal diet only and used as controls.

Five birds from each group were slaughtered every week. Three duplicate samples of muscles and liver were separately analysed for estrogen (17-estradiol) content by using high pressure liquid chromatography (HPLC) as described earlier [3]. Hormone values are reported as means \pm standard error of the mean.

Liver specimens from each group were fixed for electron microscopy 1 hour in 2% glutaraldehyde with 0.1M cacodylate phosphate (pH 7.6) and were postfixed 15 minutes in 1M OsO₄. They were then washed in a buffer, dehydrated in a graded ethanal series, followed by propylene oxide, and embedded in Araldite. Sections were cut on a LKB-III ultramicrotome, stained with uranyl acetate and lead citrate, and examined in a Joel X-100 electron microscope.

Results

The present data demonstrate clearly that daily treatment of chickens with oral contraceptive for four weeks increases significantly 17-estradiol levels in liver and muscle by comparison with controls (Table 1). Residue concentrations determined in liver samples were higher than in muscle samples.

Electron microscopy of hepatocytes of oral contraceptive-treated chicken showed an irregular and dilated nuclear envelope

Table 1 Estrogen concentrations in tissues of treated and untreated chickens

Tissue	Week	Group A Anovlar	Group B DMBA	Group C DMBA + Anovlar	Group D Control
Muscle	1	0.576 ± 0.04	0.045 ± 0.01	0.478 ± 0.02	0.102 ± 0.02
	2	0.411 ± 0.04	0.052 ± 0.02	0.413 ± 0.07	0.085 ± 0.01
	3	0.427 ± 0.04	0.041 ± 0.01	0.374 ± 0.03	0.036 ± 0.01
	4	0.337 ± 0.04	0.020 ± 0.01	0.277 ± 0.02	0.057 ± 0.01
Liver	1	0.907 ± 0.04	0.135 ± 0.02	0.873 ± 0.04	0.147 ± 0.02
	2	0.690 ± 0.01	0.124 ± 0.02	0.503 ± 0.05	0.110 ± 0.03
	3	0.677 ± 0.09	0.115 ± 0.02	0.579 ± 0.02	0.131 ± 0.03
	4	0.572 ± 0.03	0.051 ± 0.01	0.546 ± 0.05	0.118 ± 0.09

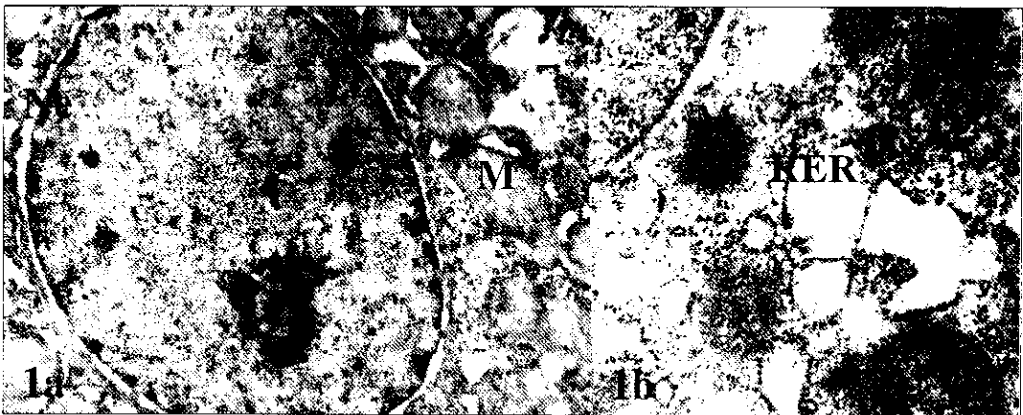

Figure 1 Electron micrograph of section of liver of Anovlar-treated chickens, showing irregular and dilated nuclear envelope (Ne), vacuolated mitochondria (M) and dilated rough endoplasmic reticulum (RER) with partial loss of attached ribosomes (→)
 a (x 10 000)
 b (x 20 000)

(Fig. 1). Also, the vacuolation of mitochondria was observed. A common abnormality is the partial loss of ribosomes from the membrane of the rough endoplasmic reticulum (RER), with moderate dilation of the cisternae and loss of aggregation into paral-

lel arrays by comparison with controls (Fig. 4). Free ribosomes are not commonly seen in the cytoplasm.

The ultrastructure of liver of DMBA or DMBA + oral contraceptive-treated chickens demonstrated the irregularity and dila-

tion of the nuclear envelopes (Figs. 2 and 3). Mitochondria displayed varying degrees of vacuolation. Gross distortions of the rough

endoplasmic reticulum were frequent. Increased dilation in the RER with partial loss of attached ribosomes was observed.




Figure 2 Electron micrograph of section of liver of DMBA-treated chickens showing the dilated nuclear envelope (Ne), pleomorphic mitochondria (M) and dilated rough endoplasmic reticulum (RER) with partial loss of attached ribosomes (→)
 a (x 10 000)
 b (x 20 000)

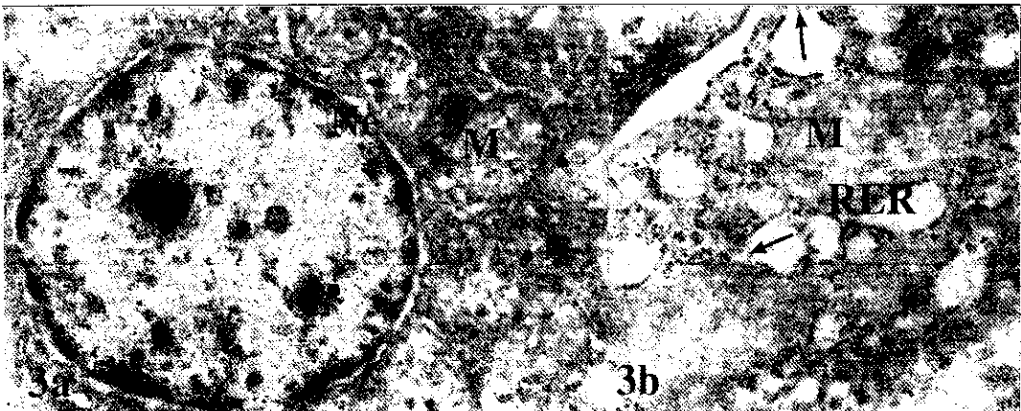

Figure 3 Electron micrograph of section of liver of DMBA + Anoviar-treated chickens, showing irregular and dilated nuclear envelope (Ne), vacuolated mitochondria (M) and dilated rough endoplasmic reticulum (RER) with partial loss of attached ribosomes (→)
 a (x 10 000)
 b (x 20 000)

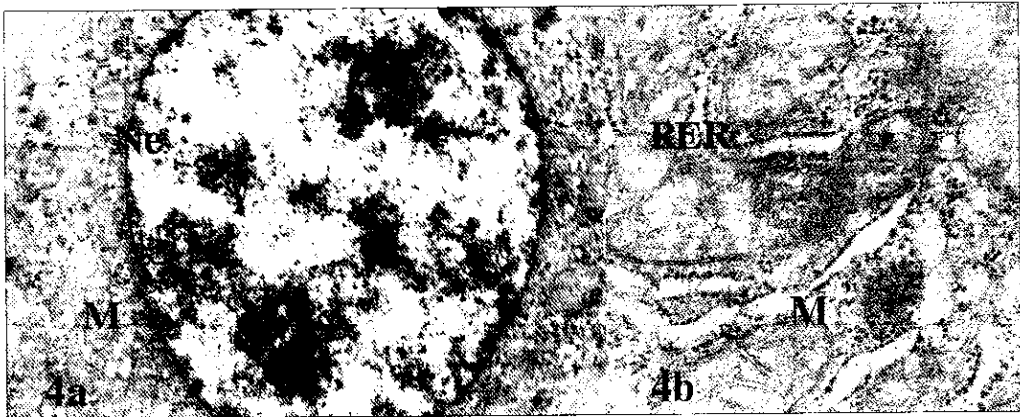

Figure 4 Electron micrograph of section of liver of control chickens showing nuclear envelope (Ne), mitochondria (M) and rough endoplasmic reticulum (RER)
 a (x 10 000)
 b (x 20 000)

Discussion

Feeding chickens with oral contraceptive steroids (Anovlar) leads to the formation of high estrogen residues in muscle and liver by comparison with controls.

Electron microscopy of the liver of oral contraceptive-treated chicken reveals interesting changes at the ultrastructural level. These alterations involve both the nucleus and cytoplasmic organelles. The nuclear envelope is evidently irregular and obviously dilated as in the case of DMBA-treated chicken. Irregularity of nuclear configuration has been reported to occur in nuclei of tumour cells [4]. It is worth mentioning that DMBA is among the most potent chemical carcinogens known to date and has been shown to induce tumours in different animal species [5,6].

The electron micrographs also clearly demonstrate that contraceptive pills are capable of changing mitochondrial structure. The vacuolation of mitochondria in the liver

of chickens fed with oral contraceptive pills was observed. In contrast, mitochondria with a few cristae and varying degrees of vacuolation were observed in the liver of toads fed with DMBA [7]. Also, this phenomenon has been observed in rats after exposure to carcinogenic substances [8]. It is well known that mitochondrial functional or structural abnormality is one of the most sensitive indicators of cell injury [9].

The ultrastructural results revealed gross distortions in the RER in Anovlar-treated chickens, observed as moderate dilation of the RER cisternae and the detachment of ribosomes over some areas of the cisternal membranes. Similar abnormalities in the RER were observed in the DMBA-treated group. The same abnormalities in the RER have been reported by Ghadially and Parry [10] in human hepatocellular carcinoma, and by Smuckler [11] in carbon tetrachloride-induced liver injury in the rat.

The fine structure of hepatocytes of DMBA + Anovlar-treated chickens reveals

nuclear and cytoplasmic changes similar to those in DMBA or Anovlar-treated animals by comparison with controls. Several workers have suggested that oral contraceptive steroids can act as promoters [12,13]. It is well known that the synthetic estrogens have been shown to stimulate liver cell proliferation [14]. On the other hand, the results of several studies have described the appearance of hepatocellular carcinoma in women using oral contraceptive steroids for prolonged periods of time [15].

From the results obtained in this work, it is suggested that oral contraceptives have a serious detrimental impact on the livers of chickens, and these hazardous effects are

similar to those induced by DMBA in chickens. It is concluded that the use of oral contraceptive steroids in chickens as anabolic agents entails a special risk to the experimental animal, and probably to the consumer. Laws and regulations concerning the use of anabolic agents in chicken and meat should be updated to prohibit their use.

Acknowledgements

The authors gratefully acknowledge the support given by the World Health Organization for this work. The help of Professor Hoffmann, Ambulanz und Geburtshilfe Veterinärklinik der Justus-Liebig-Universität Giessen, Giessen, Germany, in reviewing this manuscript is appreciated.

References

- Hoffmann B. Use of radioimmunoassay procedures for the determination of sex hormones in animal tissues. *J Steroid Bio-chem*, 1983, 19:947-51.
- Hoffmann B, Evers P. Anabolic agents with sex-hormone like activities: problems of residues. In: Rico G, ed. *Drug residues in animals. Veterinary science and comparative medicine*. Academic Press, 1986:111-46.
- Van der Water, Haagsma N. Chromatographic methods for the analysis of veterinary drug residues. *J Chromatography*, 1987, 411-415.
- Ghadially FN. *Diagnostic electron microscopy of tumours*, 2nd ed. London, Butterworths and Co. (Publishers) Ltd., 1985.
- Iversen OH. The skin tumorigenic and carcinogenic effects of different doses, numbers of dose fractions and concentrations of 8, 12-dimethylbenz[*a*]anthracene in acetone applied on hairless mouse epidermis. Possible implications for human carcinogenesis. *Carcinogenesis*, 1991, 12:493-502.
- Sadek IA. The Egyptian toad as a sensitive model to show the effect of corn oil on liver tumour induced by DMBA. *Nutr Res*, 1986, 6:333-35.
- Sadek IA, Abdul-Salam FA. Effect of dietary fat on toad liver tumour induced by DMBA ultrastructural studies. *Histol Histopath*, 1994, 9:423-26.
- Bannasch P. The cytoplasm of hepatocytes during carcinogenesis. Electron and light investigations of the nitrosemorpholine intoxicated rat liver. *Rec Res Cancer Res*, 1968, 19:1-100.
- Roodyn DB, Wilkie D. *The biogenesis of mitochondria*. London, Methuen, 1968.
- Ghadially FN, Parry EW. Ultrastructure of a human hepatocellular carcinoma and surrounding non-neoplastic liver. *Cancer*, 1966, 19:1989-2004.
- Smuckler EA. Structural and functional changes in acute liver injury. *Environ Health Pros*, 1976, 15:13.

12. Sadek IA, Abdelmeguid N. Enhancement of liver tumour in the Egyptian toad by oral contraceptive steroids. *J Nutr Growth and Cancer*, 1986, 3:239-44.
13. Schuppler J, Gunzel P. Liver tumors and steroid hormones in rats and mice. *Arch Toxicol*, 1979, 2:181-95.
14. Cole FM, Sweeney GD. Changes in rat hepatocyte plasma membranes caused by synthetic estrogens. *Lab Invest*, 1980, 42:225-30.
15. Henderson BE et al. Hepatocellular carcinoma and oral contraceptives. *Br J Cancer*, 1983, 48:437-44.

